

1-1-1955

Histological and histochemical studies of growth changes of canine skin.

James Edgeley Lovell
Iowa State College

Follow this and additional works at: <https://lib.dr.iastate.edu/rtd>

 Part of the [Veterinary Anatomy Commons](#)

Recommended Citation

Lovell, James Edgeley, "Histological and histochemical studies of growth changes of canine skin." (1955). *Retrospective Theses and Dissertations*. 18448.
<https://lib.dr.iastate.edu/rtd/18448>

This Thesis is brought to you for free and open access by the Iowa State University Capstones, Theses and Dissertations at Iowa State University Digital Repository. It has been accepted for inclusion in Retrospective Theses and Dissertations by an authorized administrator of Iowa State University Digital Repository. For more information, please contact digirep@iastate.edu.

QP88.5
L 943h
c. 2

HISTOLOGICAL AND HISTOCHEMICAL STUDIES OF
GROWTH CHANGES OF CANINE SKIN

by

James Edgeley Lovell

A Thesis Submitted to the
Graduate Faculty in Partial Fulfillment of
The Requirements for the Degree of
MASTER OF SCIENCE

Major Subject: Veterinary Anatomy

Signatures have been redacted for privacy

Iowa State College

1955

1495785

TABLE OF CONTENTS

	Page
I. INTRODUCTION	1
II. REVIEW OF LITERATURE	3
A. General	3
B. Epidermis	3
C. Dermis.	6
D. Hair and Hair Follicles	7
E. Sweat Glands.	9
F. Sebaceous Glands.	10
G. Arrector Pili Muscle.	12
III. METHODS OF PROCEDURE	13
A. Obtaining Skin Samples.	13
B. Histological and Histochemical Methods	15
IV. OBSERVATIONS	19
A. Epidermis	19
B. Dermis.	31
C. Hair Follicles.	40
D. Sweat Glands.	45
E. Sebaceous Glands.	51
F. Arrector Pili Muscles	54
V. DISCUSSION	57
A. Epidermis	57
B. Dermis.	59
C. Hair Follicles.	61
D. Sweat Glands.	65
E. Sebaceous Glands.	66
F. Technique for Acid and Alkaline Phosphatase	66
VI. SUMMARY.	69
VII. CONCLUSIONS.	74
VIII. LITERATURE CITED	76

	Page
IX. ACKNOWLEDGMENTS.	82
X. PHOTOGRAPHS.	83

I. INTRODUCTION

The control and treatment of canine skin disorders has been a perplexing problem for many years, for both the dog owner and the veterinarian. The methods used to combat cutaneous involvements of the dog have not been entirely satisfactory because of an incomplete knowledge of the physiological and pathological factors involved. A vast amount of research has been done on the anatomy, physiology, and pathology of human skin. With a basic understanding of the structure and function of the skin, human dermatologists are able to attack skin problems on a scientific level. Unfortunately, very little of the information and experience developed in human dermatology is directly applicable to veterinary medicine because of differences between the skin of man and animals. Due to a lack of information concerning the normal histological structure of the skin of the dog, physiological and pathological studies of canine skin have been retarded.

A review of the literature reveals that histological work done on the skin of the dog, in the past, was largely confined to morphological studies. The bulk of these studies have been done on random dogs with very little consideration of their ages.

The histochemical study of the anal sac of the dog by

Montagna and Parks (1948) and the cytochemical study of the circumanal glands of the dog by Parks (1950) are the only investigations, known to the author, into the histochemical or cytochemical nature of canine skin.

This study, therefore, is an attempt to determine the changes that take place in canine skin between birth and 28 weeks of age, utilizing histological and histochemical methods.

II. REVIEW OF LITERATURE

A. General

Literature concerning the microscopic anatomy of the integumentary system of the dog is quite limited. The first recorded research on the histology of canine skin was done by the German worker, Gurlt (1835), in which he did a comparative study of the skin of domestic animals and man. During the century following Gurlt's work, other investigations into the structure of the dog's skin were reported in the German language. These were summarized very well by Claushen (1933). Ellenberger (1906) presented a good textbook summary of the work up to that date. Trautmann and Fiebiger (1949) also gave a textbook discussion of canine skin. Recent work has been reported by the following workers: Muto (1925), Gair (1928), Fuchs (1934), Speed (1941), Varicak (1941), Hildebrand (1952), Nielsen (1953), Webb and Calhoun (1954), Epling (1953), Hansen et al. (1950), and Hansen et al. (1954).

B. Epidermis

Hansen and co-workers (1950), in studies of the skin of dogs on normal and fat deficient diets, described

histological sections taken from the dorsal surface of the thigh and stained with hematoxylin and eosin. They found the normal epidermis to consist of two to four cell layers, and that the nuclei of the cells were oriented parallel to the surface. They observed no epidermal pegs, and that the absence of intercellular bridges caused the cytoplasm to appear syncytial. The stratum corneum was found to be thin and without nuclei. In their material, neither the stratum granulosum nor stratum lucidum was evident. In biopsies from the dorsal aspect of the thigh and from the ventral surface of the chest, fixed in Bouin's solution and stained with hematoxylin and eosin, Hansen et al. (1954) described the epidermis as being two to three cells in thickness. The outer layer was flattened to a granulosum type containing a few basophil granules. Above this layer, they described a thin lace-like stratum disjunctum of keratinized material, with hardly a trace of stratum lucidum. They found the basal layer of the stratum germinativum to be low columnar to cuboidal with little mitosis.

Webb and Calhoun (1954) described four distinct epidermal layers: stratum germinativum, stratum granulosum, stratum lucidum, and stratum corneum. According to their measurements, the epidermis varied from 26.5 microns in the sternal region to 1685.4 microns in the digital pad. They found the stratum germinativum to vary from two cell rows

in thin skin to 35 rows in the nasal septum. The stratum granulosum, varying from one row of cells in thin skin to 15 rows in the digital pad, was generally present. According to their findings, the stratum lucidum was best developed in the digital pads, and was absent in most of the thin epidermis. They found that the stratum corneum varied from 5.3 microns in the lip to 1526.4 microns in the digital pad.

Epling (1953) described the epidermis of the carpal, metacarpal, metatarsal, and digital pads as consisting of three layers: stratum germinativum, stratum granulosum, and stratum corneum. In describing the thin skin, he reported that all three layers of the epidermis are decidedly reduced in thickness, and the stratum granulosum is sometimes absent altogether.

Varicak (1941) compared the epidermal layers of the skin of the domestic animals with those of man. He found that the epidermis of the dog resembles that of man.

Webb and Calhoun (1954), Epling (1953), and Hansen et al. (1954) made comments on the junction of the epidermis and dermis. Epling mentioned a network of reticular fibers existing between the stratum germinativum and the dermis, which is commonly termed the basement membrane. Hansen described the lower surface of the epidermis as being quite smooth and resting on a rather homogeneous collagenic layer of dermis containing a few fibroblasts, capillaries, and

nerve fibers.

Mitosis in the epidermis was discussed by several authors. Hansen et al. (1954) stated that the basal layer of the stratum germinativum is low columnar to cuboidal with little mitosis. Epling (1953) reported that mitoses are most numerous in the deeper layer but also occur in other parts of the stratum germinativum. He also stated that pigment is observed as fine granules within the cells of the stratum germinativum and to a lesser degree in the remaining strata. Webb and Calhoun (1954) found that white or light colored skin was characterized by a few melanin granules in the cytoplasm of the basal layer of the stratum germinativum. The amount of pigment increased with darkness of the skin. Black skin had melanin in all layers of the epidermis. Nielsen (1953) found the hairless, heavily-pigmented skin on the tip of the nose to be without sweat glands.

Trautmann and Fiebiger (1949) stated that the planum nasale of Carnivora is free from glands.

C. Dermis

Epling (1953) stated that the dermis of the hairy skin of the dog is composed of dense irregularly arranged elastic, collagenous, and reticular fibers, along with

fibroblasts and histiocytes. Hansen et al. (1950) found the dermis to consist of sharply demarcated and loosely woven collagen bundles and blood vessels.

Webb and Calhoun (1954) found that collagenous and elastic fibers were finer in the superficial or papillary zone of the dermis, and thicker in the deep or reticular layer. They noted numerous reticular fibers just beneath the basement membrane and around hair follicles. Sisson and Grossman (1953) stated that the corium of the foot pads have large papillae and contain sweat glands and lamellar corpuscles.

D. Hair and Hair Follicles

A comprehensive study of the hair of the costal region of the dog was done by Gair (1931). He observed hair length, thickness, type, and number of hairs per square millimeter, and classified the hair coats of dogs into three types: normal, short, and long.

The hair follicle of the dog has been discussed by various authors. Sisson and Grossman (1953) stated that the hairs in the dog's skin are arranged in groups of three to a large extent. According to Hansen et al. (1950), the hair follicles from the skin of the dorsal surface of the thigh have an epidermal layer of two to three cells. Epling

(1953) stated that the hair follicle is essentially an epithelial invagination of the skin, and that it is common to find that many hairs may share the upper portion of a follicle, and more deeply, branch away from one another to form individual follicles. As many as 13 hairs may share one hair follicle. Claushen (1933) found that the hairs occur in groups, and each group consists usually of only one main hair and three to nine accessory hairs, all of which arise out of a common hair bed. Fuchs (1934) reported that on the head and limbs, the hairs lie in contiguous groups, each with a principal hair and associated accessory hairs. Hildebrand (1952, p. 421) gives the following monograph on the hair follicles of canids by de Meijere (1894):

On the well-furred parts of the bodies of many mammals, each hair follicle becomes divided and produces a bundle of hairs. In canids, the bundles may be isolated, but are usually in groups of two to four or more; three-bundle groups are by far the most frequent. The groups are oriented into somewhat irregular rows. The typical bundle consists of several wool or under hairs and a single longer and stiffer guard or over-hair. The guard-hair of the central bundle of a three-bundle group is coarser than that of the lateral bundles.

Ellenberger and Baum (1943) describe the arrangement of hairs in groups in the dog, and show illustrations of a main hair with a group of smaller hairs clustered around it. Also, they show an illustration of the surface contour of the skin with the bunches of hairs grouped in three's, emerging from under folds of the surface.

E. Sweat Glands

Gurlt (1835) was the first to record research into sweat glands of horses, cattle, pigs, and dogs. In the dog, he found that in all hairy parts, the sweat glands are small and elongated, not very curved, and not easily found.

The work of Claushen (1933) contains a comprehensive review of the German literature and includes the observation that sweat glands are present in all parts of the skin. Their ducts open into the hair follicle above the sebaceous gland, 300 to 500 microns under the epidermis. Fuchs (1934) found that the sweat glands are most numerous on the distal end of the limbs, next on the lips, then the hairy part of the nose, and about as many on the proximal ends of the limbs.

Speed (1950) gives a very good survey of the literature in English and gives histological evidence for the following conclusions, page 256:

Sweat glands in the dog are numerous. They occur in a simple uncoiled form on the hairy parts of the body. In the pads of the feet, they are coiled. With the exception of those in the pads of the feet, all sweat glands in the dog open into hair follicles and have the appearance of buds or branches of the hair follicle. Contrary to Hirt's findings, the opening of the sweat gland into the hair follicle is separate from that of the sebaceous gland, and nearer the surface of the skin.

Aoki and Wada (1951) suggest that the sweat glands in the hairy skin of the dog do not participate actively in the central thermo-regulatory mechanism but that they subserve chiefly for the protection of the skin from excessive rise of temperature.

Trautmann and Fiebiger (1949) stated that the apocrine glands of the dog are serpentine small tubular glands, that are better developed in some regions, such as the back, mouth, and anus. Nielsen (1953) classified the sweat glands of the dog into merocrine and apocrine, according to the classification of Schaffer (1924). Nielsen stated that the apocrine glands of the dog are large loosely-coiled sweat glands, distributed over the entire skin as an appendix to the hair follicles. The small densely-coiled merocrine sweat glands are present only in the thick fatty fibrous tissue under the foot pads. He included a description of the secretion and resting cycle of the apocrine glands with photomicrographs.

F. Sebaceous Glands

In writing on the skin of the dog, Sisson and Grossman (1953) stated that sebaceous glands are best developed in short and rough haired breeds; and that they are largest and most numerous at the lips, anus, dorsal surface of the

trunk, and sternal region. Fuchs (1934) reported that sebaceous glands occur in elongated and alveolar forms and of varying sizes, the largest being on the head, the lip, and the hairy part of the nose. Claushen (1933) found sebaceous glands present in all parts of the skin that he examined. Trautmann and Fiebiger (1949) stated that, in the dog, sebaceous glands are often club-shaped and coiled, or even branched. Webb and Calhoun (1954) reported that the sebaceous glands of the dog were generally larger than those of the human species. Nielsen (1953) stated that glands with a sebaceous holocrine type of secretion are distributed over the entire integument in connection with the hairs. Morphologically, they do not differ from the sebaceous glands in the skin of other mammalian species. Epling (1953) described the histological structure of sebaceous glands of the dog. Hansen et al. (1954) stated that at the level of the stratum reticularis, sebaceous glands are bunched on the sides and lower slope of the follicle. They show a complete gradation from germinative to degenerative cells, with little sign of a lumen in any gland. According to Schaffer (1930), all sebaceous glands are developmentally related to hair follicles.

G. Arrector Pili Muscle

Very little has been written about the arrector pili muscle of the dog. Claushen (1933) reported that arrector pili muscles are strongly developed on the back and often absent in the remaining parts of the body. Epling (1953) agreed that the arrector pili muscles are best developed in the dermis of the dorsal aspect of the body. He also stated that each muscle arises in the dermis by several ends, runs a short distance as a compact bundle, then divides into smaller branches which serve the individual hairs of a group.

III. METHODS OF PROCEDURE

A. Obtaining Skin Samples

The specimen material was secured from 13 dogs, which were whelped and raised in the dog colony of the Veterinary Anatomy Department, Iowa State College. At the time of whelping, the birth dates were carefully recorded so that the age of the dogs would be definitely known. After weaning, the dogs were fed dry commercial dog food¹ in self feeders.

Half of the protein of the commercial dog food was from animal sources, one-third from special vegetable sources, and one-sixth from cereals. The food provided 1500-1600 calories per pound. The dogs were allowed all the water they wanted by means of automatic waterers. Intestinal parasites were controlled by treating the bitches with a commercial anthelmintic prior to parturition, and cleaning the dog runs daily. Protection against canine distemper and infectious hepatitis was afforded by means of a double fence with a five-foot alleyway around the dog runs to

¹The information concerning source and caloric value of the feed was obtained from a report of the Gaines Research and Development Laboratory, October 2, 1953.

prevent exposure by stray dogs. There was no evidence of excessive parasitism or nutritional deficiency observed during the feeding period or at the time the material was collected. The sex, breed characteristics, and age, at the time the skin samples were collected, were as follows:

Birth	- Coon hound	Female
1 week	- Coon hound	Female
2 weeks	- Coon hound	Female
3 weeks	- Coon hound	Female
4 weeks	- Collie cross	Male
6 weeks	- Collie cross	Female
8 weeks	- Collie cross	Female
10 weeks	- Coon hound	Female
12 weeks	- Coon hound	Female
16 weeks	- Coon hound	Male
20 weeks	- Coon hound	Male
24 weeks	- Cocker cross	Female
28 weeks	- Cocker cross	Female

At the specific ages the dogs were destroyed by electrocution and the specimen material was immediately collected from the body areas shown on Fig. 1. The strips of skin were cut parallel with the direction of the slant of the hair, whenever possible. Two samples of skin were collected from each area. One, 1/2 centimeters by 2 centimeters, was fixed in formalin; the other, 2-3 millimeters by 2 centi-

meters, was fixed in chilled alcohol.

B. Histological and Histochemical Methods

1. Histological techniques

For a general fixative, a 10 per cent solution of neutral formalin (equal to 4 per cent of formaldehyde) was used. The skin samples were allowed to remain in the formalin fixative for 24 to 48 hours. After the fixation period, the hair was trimmed as short as possible. The edges of the samples were trimmed square with a razor blade and the samples were stored in 70 per cent ethyl alcohol. Dehydration and embedding were accomplished through butyl alcohol and Altmann's mixture, using the technique of Johnson *et al.* (1943) for muscle, which was modified by reducing the time in each paraffin mixture to 30-60 minutes, making a total of 2-4 hours in the paraffin oven. It was found that the skin samples became too hard if they were allowed in the oven more than 3-4 hours.

Sections of the paraffin blocks, 6-10 microns in thickness, were routinely stained with Harris' alum hematoxylin, Mallory (1938, p. 72), and precipitated eosin Y technique according to Pearson (1942). For the staining of specific structures, the following three staining techniques were

used in succession: Van Gieson's acid fuchsin and picric acid stain for collagenous fibers (Guyer, 1936, p. 250); Weigert's stain for elastic fibers (Mallory, 1938, pp. 168-169); and Heidenhain's iron hematoxylin for nuclear detail (Mallory, 1938, pp. 74-75). For the demonstration of reticular fibers, the rapid method of silver impregnation of reticulum according to Foot and Menard (1927) was used.

2. Glycogen technique

For the demonstration of glycogen, the tissue was fixed in 80 per cent alcohol at zero degrees Centigrade, cleared in cedar oil, and embedded in paraffin. The sections were cut at 6-10 microns and stained with the Feulgen-Bauer technique (Bensley, 1938, p. 105). Control sections were stained simultaneously from which the glycogen had been digested in saliva or diastase.

3. Phosphatase techniques

For the histochemical demonstration of alkaline and acid phosphatase, the methods of Gomori (1952) were followed. The calcium phosphate method was used for the demonstration of alkaline phosphatase, and the lead method was used for the demonstration of acid phosphatase. Dempsey and Deane

(1946) found that chilled alcohol was satisfactory for the fixation and demonstration of both alkaline and acid phosphatase.

The skin samples were cut at 2 millimeters in thickness and fixed in cold 80 per cent alcohol (zero degrees Centigrade) for 24 hours. They were then changed every 24 hours to 90 per cent, 95 per cent, and finally absolute alcohol.

The tissues were cleared in cedar oil for 24 hours and then placed in three changes of benzene of 1 hour each. Infiltration was accomplished by means of three changes of low melting point paraffin. The tissues were not allowed in the paraffin oven for more than 3 hours. Altmann's mixture was used as the final embedding medium. The paraffin blocks were trimmed and sectioned from 6-10 microns in thickness, and mounted on glass slides by means of Mayer's albumin-glycerine mixture.

After deparaffinization, the sections were incubated in calcium solutions, containing sodium glycerophosphate and either lead or calcium ions. The solutions were buffered with acetate or sodium barbital, depending on the pH desired. All solutions were examined immediately prior to incubation by means of a Beckman pH meter and were adjusted to Ph 9.4 for alkaline phosphatase and pH 5.0 for acid phosphatase. The sections were incubated for 6, 12,

and 24 hours. Control sections were prepared by omitting the substrate in the incubating solutions, in order to reveal any possibilities of preformed insoluble native phosphate. The sites of phosphatase activity were made visible microscopically by converting the precipitated phosphate into visible brown sulfides as described by Gomori (1939).

4. Microscopic techniques

Observations of the stained sections were made by means of a Bausch and Lomb binocular research microscope. The measurements were made with a Bausch and Lomb eyepiece micrometer.

Some observations of the surface contour of fresh skin and the arrangement of the hairs and hair follicles, to confirm the microscopic observations made from the sections, were made by means of an American Optical Company binocular dissecting microscope at 15X magnification.

IV. OBSERVATIONS

A. Epidermis

In the epidermis of the foot pads, five layers of epithelium were observed: stratum cylindricum, stratum spinosum, stratum granulosum, stratum lucidum, and stratum corneum. The stratum cylindricum and stratum spinosum are frequently referred to collectively as the stratum germinativum.

The stratum cylindricum was made up of a single layer of basal cells resting on the connective tissue of the dermis. The cells of this layer had little cytoplasm and dark staining nuclei which occasionally showed mitotic activity.

The stratum spinosum was observed to be composed of diamond or dome shaped cells containing more cytoplasm and lighter staining nuclei than the stratum cylindricum. In the foot pads and planum nasale, cell outlines and intercellular bridges were observed. In the hairy skin, the stratum spinosum cell outlines were more visible after alcohol fixation than following formalin.

The stratum granulosum was made up of flattened cells which contained basophilic keratohyalin granules in their cytoplasm. The stratum granulosum was the thickest in the foot pad epidermis. In the thin hairy skin, the stratum

granulosum was one to three cells in thickness; whereas, in the foot pad, it was four to five cell layers thick.

The stratum lucidum was consistently observed only in the foot pads as a shiny acidophilic layer of homogenous substance called eleidin by Maximow and Bloom (1952). This layer was lacking entirely in the planum nasale and was inconstant in the thin hairy skin, being observed only in the thicker regions.

The stratum corneum was observed to consist of a layer of flattened, filamentous, keratinized, non-nucleated material. The stratum corneum of the planum nasale was very thin in comparison to the thickness of the epidermis. The cells of the corneum of the nasal region contained nuclei. The stratum corneum made up from one-third to one-half of the total thickness of the epidermis in all areas studied, with the exception of the planum nasale.

The measurements of the epidermis include the thickness of all of the layers present including the stratum corneum. The counts of the number of layers of cells in the epidermis do not include the stratum corneum or stratum lucidum because of their non-cellular nature.

The areas of non-hairy thick epidermis, like the planum nasale and foot pads, increased in thickness with an increase in age.

Table 1 shows the measurements that were made, of all

Table 1. Thickness of epidermis in various body areas at various ages
(measured in microns with an eyepiece micrometer)

	Birth	Age in weeks											
		1	2	3	4	6	8	10	12	16	20	24	28
Interscapular	37	30	28	25	32	32	32	36	32	38	31	39	39
Front foot pad	225	520	360	472	750	652	877	900	870	990	950	1620	1800
Sacral	36	36	32	35	32	40	36	34	33	40	38	40	42
Hind foot pad	210	468	500	495	702	720	895	990	900	900	1061	1790	1800
Paraumbilical	35	35	40	46	35	30	42	35	33	55	32	32	33
Planum nasale	194	234	300	220	225	270	450	396	405	540	620	640	630
Margin of teat	35	52	51	50	40	34	46	43	35	56	40	25	60
Hairy eyelid	37	25	45	43	32	28	36	40	40	30	26	28	23
Eyelid margin	59	68	60	75	70	62	80	81	56	60	72	69	84
Conjunctiva	48	43	45	53	47	47	60	49	46	48	55	59	45
Fold of flank	46	49	46	47	43	49	41	49	45	50	42	40	36
Ear flap	34	23	61	32	37	40	28	41	38	45	42	26	20

layers, of the various areas at different ages. The epidermis of the foot pads increased from 225 microns at birth to 1800 microns at 28 weeks. The epidermis of the planum nasale increased from 194 microns at birth to 630 microns at 28 weeks.

Table 1 also shows that the regions of hairy skin, like interscapular, sacral, paraumbilical, margin of teat, hairy eyelid, fold of flank, and ear flap, remained quite constant, 25 to 50 microns, during the 28 weeks studied. The non-hairy margin of the eyelid was thicker, measuring 56-84 microns in thickness. The conjunctiva was found to be thicker than the epidermis of the hairy areas, 43-60 microns.

Fig. 2 and Fig. 3 show a comparison of the thickness of epidermis of the planum nasale at birth and 28 weeks. Both photomicrographs were taken at the same magnification.

Figs. 5, 7, and 9 show photomicrographs of the epidermis of the foot pad from birth, 8 weeks, and 28 weeks, respectively. They were taken at the same magnification. The increase in thickness is readily observed.

Figs. 4, 6, and 8 show photomicrographs of the epidermis of the hairy skin at birth, 8 weeks, and 28 weeks, respectively, taken at the same magnification. The similarity in thickness of the epidermis at these three ages is easily seen.

Table 2 shows the average number of cell layers counted

Table 2. Thickness of epidermis in various body areas at various ages
 (values represent the average number of cell layers, not
 including the stratum lucidum or stratum corneum)

	Birth	Age in weeks											
		1	2	3	4	6	8	10	12	16	20	24	28
Interscapular	3	5	4	3	6	4	5	4	5	5	5	5	5
Front foot pad	9	18	18	16	12	14	16	15	18	18	17	18	20
Sacral	4	3	5	4	5	4	5	4	5	4	5	5	5
Hind foot pad	12	18	15	17	16	15	17	16	20	18	15	16	20
Paraumbilical	4	8	6	6	5	4	5	4	5	6	7	4	5
Planum nasale	10	14	19	25	15	20	18	18	21	21	25	23	19
Margin of teat	4	8	6	6	5	4	5	5	4	5	5	5	5
Hairy eyelid	6	6	5	5	4	5	5	4	6	4	7	5	5
Eyelid margin	9	10	9	10	9	9	11	9	11	10	11	10	10
Conjunctiva	8	7	8	10	7	9	8	6	8	6	8	7	6
Fold of flank	5	6	4	6	4	6	5	5	6	5	7	5	4
Ear flap	6	5	6	4	5	5	6	5	5	6	6	4	5

in the stratum cylindricum, spinosum, and granulosum in the various body areas at different ages. There was very little fluctuation in the number of cell layers of the epidermis of the hairy skin. The areas of thick skin, like the foot pads and planum nasale, increased slightly in the number of cell layers during the 28 weeks studied. It was observed that most of the increase in thickness in the foot pads was a result of the increased undulation of the basal layer of epidermal cells to form epidermal pegs and an increase in thickness of the stratum corneum, rather than an increase in number of cell layers.

Table 3 gives the distribution and location, according to ages, in which epidermal papillae were observed. These papilla-like structures were covered by a thickened epidermis which was usually 6-12 cell layers thick, about twice as thick as the surrounding epidermis. The dermis under this area was thickened, more dense and filled or extended up under the thickened epidermis to form a papilla-like structure. Fig. 10 shows a picture of an epidermal papilla which was taken through a dissecting microscope at 15X magnification. Figs. 11, 12, and 13 show photomicrographs of sections of epidermal papillae.

Many clear cells were observed in the stratum cylindricum. The cytoplasm of the cells appeared to be completely transparent and the nuclei were extremely basophilic. These

Table 3. Epidermal papillae were observed in skin sections taken from various body areas at various ages as indicated below

	Birth	Age in weeks											
		1	2	3	4	6	8	10	12	16	20	24	28
Interscapular	Pap*	Pap	-	-	Pap	-	Pap	-	-	-	-	-	Pap
Front foot pad	-	-	-	-	-	-	-	-	-	-	-	-	-
Sacral	-	-	-	-	Pap	-	-	-	-	-	-	Pap	-
Hind foot pad	-	-	-	-	-	-	-	-	-	-	-	-	-
Paraumbilical	Pap	-	-	-	-	-	-	-	Pap	Pap	-	-	-
Planum nasale	-	-	-	-	-	-	-	-	-	-	-	-	-
Margin of teat	Pap	-	-	-	-	-	-	Pap	-	-	-	-	-
Eyelid	-	-	-	-	-	-	-	-	-	-	-	-	-
Fold of flank	Pap	-	-	-	-	-	-	-	-	-	-	-	-
Ear flap	-	-	-	-	-	-	-	-	-	-	-	-	-

*The abbreviation Pap indicates the presence of papillae

clear cells were more numerous in the stratum cylindricum of the thick skin of the planum nasale and foot pad than in the hairy skin, as can be seen by comparing Fig. 14 and Fig. 15. Many of these clear cells showed evidence of mitotic activity as illustrated in Fig. 16 and Fig. 17, which show cells in telophase. Because the nuclear material of the clear cells stained so intensely basophilic and was observed in various stages of mitosis, it was assumed that all clear cells with the dark basophilic nuclei represented mitotic cells. Table 4 gives the counts of mitotic figures that were made on this basis, of various areas at different ages. The columns of the table were totaled both vertically and horizontally. Vertically there was no apparent correlation between age and number of mitotic figures per section. Horizontally it appeared that the number of mitotic figures was greater in the foot pads and planum nasale than in the thin hairy skin.

Table 5 shows the distribution of glycogen in the epidermis of various body areas at various ages. In the hairy skin, very little glycogen was observed. Only a few very fine granules were observed around the openings of hair follicles. In the thick skin of the foot pads and planum nasale, glycogen granules were observed in the cytoplasm of the spinous cells, only in the very young material.

Fig. 18 shows a section of the fused eyelids of a

Table 4. Mitotic figures in skin sections from various body areas at various ages (values represent the number of mitotic figures counted in one section)

	Birth	Age in weeks												Total
		1	2	3	4	6	8	10	12	16	20	24	28	
Interscapular	1	17	4	8	11	0	11	4	6	2	6	13	5	88
Front foot pad	0	10	5	95	0	5	33	8	3	8	16	27	5	215
Sacral	4	1	2	10	0	0	10	0	3	1	5	5	5	46
Hind foot pad	4	15	15	15	11	4	37	10	17	0	0	30	12	170
Paraumbilical	1	2	4	5	1	0	8	10	12	18	7	0	3	71
Planum nasale	2	15	10	0	7	15	13	3	8	14	8	23	5	123
Margin of teat	5	10	1	5	1	0	14	3	0	11	8	8	6	72
Eyelid	0	0	5	0	0	0	6	4	2	0	4	2	0	23
Fold of flank	5	10	0	4	0	6	8	4	0	3	2	1	0	43
Ear flap	0	0	0	2	0	3	7	8	0	2	4	4	0	30
Total	22	80	46	144	31	33	147	54	51	59	60	113	41	

Table 5. Glycogen content of epidermis in various body areas at various ages (values indicate degree of reaction to Feulgen-Bauer technique*)

	Birth	Age in weeks											
		1	2	3	4	6	8	10	12	16	20	24	28
Interscapular	0	5	0	0	5	0	0	0	0	0	0	0	0
Front foot pad	10	0	0	0	0	0	0	0	0	0	0	0	0
Sacral	5	0	0	0	0	0	0	0	0	0	0	10	0
Hind foot pad	30	5	0	0	0	0	0	0	0	0	0	0	0
Paraurbilical	5	5	0	0	5	0	5	0	0	0	0	0	0
Planum nasale	20	20	5	30	5	0	0	0	0	0	20	0	0
Margin of teat	5	0	0	0	0	0	0	0	5	0	0	0	0
Hairy eyelid	0	0	0	0	0	0	0	0	0	0	0	0	0
Conjunctiva	5	10	30	30	30	20	20	20	20	10	20	20	20
Fold of flank	0	0	0	0	0	0	0	0	0	0	0	0	0
Ear flap	5	5	5	0	0	0	0	0	0	0	0	0	0
Hairy lip	0	0	0	0	0	a							
Buccal mucosa	40	30	20	20		a							
Hairy vulva	5	5	5	5	0	a							
Mucosa of vulva	40	40	20	30	40	a							

* 5 - very slight
 10 - slight
 20 - moderate
 30 - intense
 40 - very intense

^aMaterial was not collected from the lip and vulva above the age of 4 weeks.

day old puppy with glycogen granules in the cytoplasm of the epidermal cells at the margin of fusion. Fig. 19 shows a section of mucous membrane from the vulva in which the cytoplasm of the cells contain large quantities of glycogen. The mucous membrane of the conjunctiva, lip, vulva, and prepuce all contained large quantities of glycogen as shown in Table 5.

Table 6 shows the distribution of alkaline phosphatase in the epidermis of various body areas at various ages. In the hairy skin, alkaline phosphatase was found to be present, in very small quantities, only in the nucleoli of the spinous cells of the stratum spinosum and the keratohyaline granules of the stratum granulosum. The epidermis of the thick skin, like the foot pads and planum nasale, showed a moderate to very intense reaction for alkaline phosphatase in the nuclei and cytoplasm of the cells at the depths of the epidermal pegs, which extended deep into the dermis. This may be seen in Fig. 21. The nuclei and cytoplasm of the cells of the mucous membranes showed the strongest reaction. The mucosa of the vulva and lip reacted to a degree of very intense, as seen in Fig. 20.

In heavily pigmented parts of the skin, many of the basal cells contained a large amount of pigment. These probably represent melanoblasts. The ordinary epidermal cells also contained melanin granules on the distal side of

Table 6. Distribution of alkaline phosphatase in epidermis of various body areas at various ages (values indicate degree of reaction to the Gomori technique*)

	Birth	Age in weeks											
		1	2	3	4	6	8	10	12	16	20	24	28
Interscapular	0	5	5	5	0	0	0	5	5	0	0	5	0
Front foot pad	20	20	20	30	30	20	30	30	30	20	30	40	20
Sacral	0	0	5	5	0	0	0	0	0	5	0	5	0
Hind foot pad	20	20	30	30	30	20	30	30	20	20	40	40	30
Paraumbilical	0	5	5	5	5	0	0	20	20	10	5	10	0
Planum nasale	40	20	20	40	30	20	20	30	20	20	40	40	20
Margin of teat	0	5	5	5	0	0	0	5	0	0	0	5	0
Hairy eyelid	0	0	5	0	0	0	0	0	0	0	10	0	0
Conjunctiva	20	20	30	20	30	30	30	30	20	30	30	30	30
Fold of flank	0	5	5	5	0	5	0	5	0	0	5	10	0
Ear flap	0	5	5	5	0	5 ^a	0	5	5	0	0	10	0
Hairy lip	5	0	5	0	0								
Buccal mucosa	40	40	40	40	40								
Hairy vulva	5	0	10	5	0								
Mucosa of vulva	40	40	40	40	40								

* 5 - very slight
 10 - slight
 20 - moderate
 30 - intense
 40 - very intense

^aMaterial was not collected from the lip and vulva above the age of 4 weeks.

the nucleus in varying amounts, depending on the degree of pigmentation of the area. Fig. 22 shows a pigment cell which has dendritic processes. This cell type is suggestive of those described by Billingham (1948) after dopa reaction.

Fibroblasts were observed between the cells of the basal layer of epidermis as illustrated in Fig. 23. These fibroblasts were more visible in the formalin fixed tissue than in that fixed in 80 per cent alcohol.

Fig. 24 shows the difference between the dermal-epidermal junction of the mucous membrane and the hairy portion of the lip. There is no pegging of the epidermis of the hairy part of canine skin. The basal layer of cells forms a line parallel with the surface contour of the skin. The surface of the hairy skin of the dog is normally thrown up into folds, which form troughs or grooves, into the depths of which the hair follicles invaginate. The mucous membrane of the lip, as shown in Fig. 25, forms an undulating line at the dermal-epidermal junction. This is characteristic of the non-hairy portions of canine skin, like the planum nasale and foot pads.

B. Dermis

The dermis was thickest, at all ages, in the interscapular and sacral regions. As seen in Table 7, it

Table 7. Thickness of dermis in the various body areas at various ages^a
(measured in microns with an eyepiece micrometer)

	Birth	Age in weeks											
		1	2	3	4	6	8	10	12	16	20	24	28
Interscapular	720	990	495	405	518	495	675	810	830	1080	1440	1620	1575
Front foot pad	270	473	405	440	315	450	585	585	495	900	900	900	810
Sacral	630	698	563	600	563	518	810	810	585	1350	1420	1440	1530
Hind foot pad	315	405	370	585	583	518	810	675	675	900	630	630	720
Paraumbilical	324	315	338	405	405	495	675	495	585	850	630	990	495
Planum nasale	270	225	243	315	350	540	608	653	540	675	630	900	840
Margin of teat	315	405	270	315	293	450	653	495	675	810	585	1080	810
Fold of flank	225	293	270	315	360	360	315	540	720	720	585	540	810

^aThe dermis of the eyelid, lip and ear were not clearly defined and could not be measured.

increased from approximately 700 microns at birth to 1500 microns in thickness at 28 weeks of age. The paraumbilical region, margin of teat, fold of flank, foot pads, and planum nasale were all quite similar. They increased from about 300 microns in thickness at birth to about 900 microns at 28 weeks of age.

In all areas studied, it was found that the collagenous fiber bundles increased in size and number with an increase in age (see Table 8). At birth, the collagenous fiber bundles were found to average 3 to 4 microns in diameter. With an increase in age, there was a gradual increase in these bundles so that at 28 weeks of age they measured 19 to 20 microns in diameter. Concurrent with this increase in the size of bundles, there was a corresponding decrease in the size of the spaces between the fiber bundles.

With the increase in age, there was noted a definite increase in the size and number of elastic fibers in the dermis in all areas except the foot pads. In all areas, other than the foot pads, the elastic fibers increased from small branched filamentous fibers, less than one-half of one micron in diameter to the thicker undulating fibers of about 1.5 to 2 microns in diameter as shown on Table 9. The elastic fibers were not very plentiful. This can easily be observed in Fig. 27, which shows an area containing the highest proportion of elastic fibers observed. In the

Table 8. Size of collagenous fibers in the dermis of the skin of various body areas at various ages (values represent the diameter of the collagenous bundles in microns)

	Birth	Age in weeks											
		1	2	3	4	6	8	10	12	16	20	24	28
Interscapular	4	6	8	9	13	15	14	15	16	17	16	18	19
Front foot pad	2	3	7	9	14	13	15	14	16	18	16	17	20
Paraumbilical	3	4	5	7	9	8	11	13	14	16	17	20	19
Planum nasale	5	8	13	12	14	17	15	18	15	17	16	17	20

Table 9. Size of elastic fibers in the dermis of the skin of various body areas at various ages (values represent the diameter of the elastic fibers in microns)

	Birth	Age in weeks											
		1	2	3	4	6	8	10	12	16	20	24	28
Interscapular	.2	.4	.5	.4	.7	.5	.8	1.2	1.4	1.6	1.8	1.9	2.1
Front foot pad	.3	.5	.6	.4	.3	.5	.7	.8	.0	.8	.0	.5	.3
Paraumbilical	.3	.2	.2	.6	1.0	1.2	.9	1.3	1.4	1.6	1.5	2.0	1.6
Planum nasale	.2	.2	.4	.6	.8	1.0	1.0	1.3	1.6	1.7	1.5	1.3	1.2

deeper portions of the foot pads, there are some thick bundles of elastic fibers which extend down into the subcutaneous tissue under the foot pad. These are made up of dense elastic tissue mixed with reticular fibers. There were fine elastic fibers observed extending from the end of the arrector pili muscle to the basal layer of the epidermal cells, as shown in Fig. 26.

In all areas and ages studied, reticular fibers were observed in the sections prepared with Foot and Menard (1927) rapid technique of silver impregnation. It was noted that in the younger material, there were more reticular fibers in the dermis than in the older ages. At birth, there were many reticular fibers distributed throughout the dermal ground substance. With an increase in age, there was a gradual decrease in the number of reticular fibers. At four weeks of age, there was only a reticular network remaining under the basal layer of the epidermis and around the hair follicles, glands, arrector pili muscles, and blood vessels as shown on Table 10 and Figs. 28 and 29.

The reticular network was most concentrated under the mucous membrane of the conjunctiva, lip, and vulva (Fig. 31). In all areas, the reticular fibers interdigitated between the basal cells of the epidermis and were apparently continuous with the collagenous fibers of the dermis (Figs.

Table 10. Concentration of reticular fibers in the dermis of the skin of various body areas at various ages (values represent the concentration of reticular fibers as indicated below*)

	Birth	Age in weeks											
		1	2	3	4	6	8	10	12	16	20	24	28
Interscapular	40	40	30	20	10	10	10	10	10	10	10	10	10
Front foot pad	40	30	20	20	10	10	10	10	10	10	10	10	10
Paraumbilical	40	30	20	10	10	10	10	10	10	10	10	10	10
Planum nasale	30	30	10	10	10	10	10	10	10	10	10	10	10

- *40 - Very many reticular fibers distributed throughout the dermal ground substance
- 30 - Many reticular fibers distributed throughout the dermal ground substance
- 20 - Few reticular fibers distributed throughout the dermal ground substance
- 10 - Very few reticular fibers in dermal ground substance mostly concentrated around the hair follicles, glands, arrector pili muscles, and under the epidermis

30, 32, 33, and 34).

In the skin studied from birth, there were numerous nuclei in the connective tissue of the dermis. As the age increased, the number of nuclei in a given area decreased, as can be seen on Table 11. The nuclei counted in one half the microscopic field on oil immersion decreased from 65 at birth to 30 at 28 weeks of age.

In the material prepared by the Gomori technique for alkaline phosphatase, reactions were noted in the nuclei of the fibroblasts of the dermis and in the endothelial cells of the blood vessels and capillaries of the dermis. Table 12 shows the distribution of the enzyme, alkaline phosphatase, in the dermis of the various body areas at the various ages. In the interscapular and the paraumbilical areas, alkaline phosphatase activity was observed only during the first two weeks of age. In the skin from dogs older than this, no activity was observed. In the thick skin, like the foot pad and the planum nasale, alkaline phosphatase activity was observed for all ages, especially in the dermal papillae, in which the nuclei of fibroblasts and the capillary endothelium reacted quite consistently.

There was no glycogen observed in the dermis of any of the tissue studied with the exception of a few instances where it was observed in the walls of blood vessels in the form of very fine granules. These blood vessels were

Table 11. Comparative number of nuclei in the dermis of the skin of various body areas at various ages (values represent the number of nuclei counted in one-half of an oil immersion field)

	Birth	Age in weeks											
		1	2	3	4	6	8	10	12	16	20	24	28
Interscapular	75	68	55	47	41	39	41	32	33	27	34	21	20
Front food pad	66	75	79	65	66	55	57	47	35	35	38	32	42
Paraumbilical	60	53	61	60	45	32	42	41	30	34	29	24	29
Planum nasale	69	75	72	58	60	59	45	50	37	47	53	34	35

Table 12. Distribution of alkaline phosphatase in the dermis of the skin of various body areas at various ages (values represent the concentration of alkaline phosphatase as indicated below*)

	Birth	Age in weeks											
		1	2	3	4	6	8	10	12	16	20	24	28
Interscapular	30	20	10	0	0	0	0	0	0	0	0	0	0
Front foot pad	30	30	30	30	30	20	30	30	20	20	20	40	20
Paraumbilical	30	20	30	10	0	0	0	0	0	10	0	0	0
Planum nasale	30	20	20	40	10	20	10	30	30	20	30	30	30

- *40 - Very intense in fibroblast nuclei and capillary endothelium
- 30 - Intense in fibroblast nuclei and capillary endothelium
- 20 - Moderate amount of alkaline phosphatase in fibroblasts and endothelium
- 10 - Slight amount of alkaline phosphatase in fibroblasts and endothelium

usually located in the deeper portion of the dermis.

Lamellar corpuscles were observed in the subcutaneous tissue of the foot pads just below the dermis. They were only found in the four and 12 week old specimen, Fig. 35 and Fig. 36.

C. Hair Follicles

The hair follicles were found to develop from simple follicles (each follicle containing a single hair) at birth to a compound follicle (each follicle containing as many as 7 to 10 hairs) at 28 weeks. Table 13 shows the results of hairs counted per follicle in several representative areas at various ages. It is obvious from this table and from a comparison of Figs. 37, 38, 39, 40 and 4, 6, 8 that the number of hairs per follicle gradually increased concurrently with an increase in age. The additional hairs developed in accessory follicles which arose as buds from the original single follicle. The multiple hairs in the follicle diverged from one another in the deeper layers of the dermis and branched out into separate follicles, where the hairs originated from individual hair bulbs.

In the skin of the margin of the ear, it was noted that immature developing hair follicles were present. These may be seen in Fig. 41 as long epidermal pegs extending down

Table 15. Number of hairs emerging from a single follicle orifice in the various body areas at various ages

	Birth	Age in weeks											
		1	2	3	4	6	8	10	12	16	20	24	28
Interscapular	1	1	1-2	1-3	1-3	3-5	3-5	4-5	4-5	3-6	4-7	5-8	6-9
Paraumbilical	1	1-2	1-2	2	2-3	4	3-5	3-4	5	4-6	7-8	7-9	7-9
Margin of teat	1	1-2	1	2	1-3	3	5	2-5	3-4	4-6	7-8	7-9	7-9
Fold of flank	1	1	1-2	1-2	3	4	3-4	2-5	3-4	3-5	7	8-10	7-10

into the dermis. The hair matrix and dermal papillae have not yet developed in these follicles.

Tactile hairs were observed in the sections of the lip. The connective tissue portion of the follicle supporting these hairs was highly developed. A blood sinus, lined with endothelium, was observed between the outer and inner dermal sheaths. Because of this, these hairs are referred to as sinus hairs. They have been described by Trautmann and Fiebiger (1948). Fig. 42 shows a tangential section of a sinus hair.

Club hairs and resting hair follicles have been described by Rothman (1954) representing the inactive part of the human hair cycle. No evidence of club hairs or resting follicles was observed in any of the areas studied.

Table 14 and Figs. 43 and 55 show that large quantities of glycogen granules were present in the cytoplasm of the cells of the middle one third of the outer root sheath in all ages. No glycogen was present in the hair matrix cells and dermal papilla except during the first week of age. Small quantities of glycogen were also observed in the medulla of the hair shafts in most instances.

The highest concentration of alkaline phosphatase was observed in the dermal papilla of the hair bulb as shown on Table 15 and Fig. 44. No dermal papillae of hair follicles were observed which did not contain alkaline phosphatase.

Table 14. Distribution of glycogen in the hair follicles of the skin of the interscapular area at various ages (values represent the concentration of glycogen granules as described below*)

	Birth	Age in weeks											
		1	2	3	4	6	8	10	12	16	20	24	28
Upper one third	10	10	10	10	0	5	5	5	5	10	5	5	0
Middle one third	40	40	40	40	20	40	40	40	40	30	30	30	40
Lower one third	10	10	10	10	5	10	10	10	5	10	10	10	10
Hair matrix	5	5	0	0	0	0	0	0	0	0	0	0	0
Dermal papilla	5	5	0	0	0	0	0	0	0	0	0	0	0
Hair shaft medulla	5	5	5	0	0	0	5	5	10	5	5	5	5

* 5 - Very slight
 10 - Slight
 20 - Moderate
 30 - Intense
 40 - Very intense

Table 15. Distribution of alkaline phosphatase in the hair follicles of the skin of the interscapular area at various ages (values represent the concentration of alkaline phosphatase as shown below*)

	Birth	Age in weeks											
		1	2	3	4	6	8	10	12	16	20	24	28
Upper one third ^a	5	5	5	5	0	0	0	0	0	0	5	5	0
Middle one third ^a	5	5	5	5	0	0	10	10	0	5	5	5	5
Lower one third ^b	10	10	10	10	0	5	5	5	0	5	10	10	10
Hair matrix ^b	20	20	20	20	10	20	20	20	10	10	20	20	30
Dermal papilla ^c	40	40	40	40	20	30	20	30	30	30	30	40	30

- * 5 - Very slight
- 10 - Slight
- 20 - Moderate
- 30 - Intense
- 40 - Very intense

^aphosphatase located only in nucleoli

^bAlkaline phosphatase located in nuclei

^cAlkaline phosphatase located in both nucleus and cytoplasm

The nuclei of the hair matrix cells showed less evidence of alkaline phosphatase activity than the dermal papillae. The nucleoli of the middle and upper third of the root sheath showed a slight amount of alkaline phosphatase activity.

D. Sweat Glands

The heights of the secretory epithelium of the sweat glands of various body areas were measured with an eyepiece micrometer, Table 16. The merocrine glands of the foot pads had the lowest epithelium. There was considerable variation in the height of the glandular epithelium of the apocrine glands because of the variation in the stage of secretion. Fig. 48 shows that the actively secreting glandular epithelium is low cuboidal or flat in appearance. The pre-secretory stage is high columnar with apical knob-like processes of cytoplasm extending into the lumen of the tubule. The merocrine gland epithelium, of the foot pads, varied from 8 to 12 microns in height. The apocrine gland epithelium of the hairy skin varied from 10 to 25 microns in height. The greatest secretory activity was observed in the apocrine glands of the margin of the lip and vulva, and in the thin skin of the ventral part of the body. The measurement of the diameter of the glandular tubules varied

Table 16. Height of secretory epithelium of sweat glands of various body areas at various ages (values represent direct measurements with an eyepiece micrometer, expressed in microns)

	Birth	Age in weeks											
		1	2	3	4	6	8	10	12	16	20	24	28
Interscapular	15	18	10	16	12	12	10	15	15	22	18	15	20
Front foot pad	10	10	12	8	9	10	10	10	10	12	10	12	11
Paraumbilical	15	25	18	10	12	15	10	12	14	10	12	15	16
Margin of teat	15	25	25	12	18	17	10	25	10	22	16	15	15
Fold of flank	10	10	19	15	15	12 ^a	25	25	8	18	15	12	15
Margin of lip	10	18	15	20	22	^a							
Vulva or prepuce	18	23	18	20	20	^a							

^aMaterial was not collected from the lip and vulva above the age of 4 weeks

from 25 to 35 microns in the foot pad. In the apocrine glands, the diameter of the tubules varied from 30 to 90 microns in diameter. These measurements are shown on Table 17. The larger apocrine tubules appeared to be cyst-like dilatations. There was considerable variation in the diameter of the tubules because of the different stages of secretion. Figs. 45 and 46 show excretory ducts of apocrine glands emptying into a hair follicle above the level of the sebaceous glands.

Table 18 shows the comparative amounts of glycogen in the cytoplasm of the glandular epithelium in the various body areas for the various ages. Only traces of glycogen were observed in the apocrine glands near the junction of the secretory and excretory ducts. The merocrine glands of the foot pads showed the greatest concentration of glycogen, as shown in Fig. 49.

Table 19 shows the relative distribution of alkaline phosphatase in the sweat glands of the interscapular area and of the foot pad at various ages. The concentration of alkaline phosphatase was similar in all ages. The greatest concentration was observed in the myoepithelial cells, Fig. 50. The secretory cell nuclei, also, contained alkaline phosphatase to a lesser degree and the secretory cell cytoplasm showed no evidence of alkaline phosphatase activity. The reaction for alkaline phosphatase was greater in the

Table 17. Diameter of glandular tubules of sweat glands of various body areas at various ages (values represent measurements with an eyepiece micrometer, expressed in microns)

	Birth	Age in weeks											
		1	2	3	4	6	8	10	12	16	20	24	28
Interscapular	50	50	40	45	33	40	29	38	33	70	60	65	55
Front foot pad	25	33	32	30	25	33	31	30	31	33	35	35	33
Paraumbilical	40	90	40	43	40	43	30	40	45	45	50	50	40
Margin of teat	45	57	50	30	40	45	32	72	35	55	49	53	42
Fold of flank	35	63	45	55	35	35	65	60	38	45	90	82	60
Lip margin	40	80	60	65	60	a							
Vulva or prepuce	70	70	65	70	75	a							

^aMaterial was not collected from the lip and vulva above the age of 4 weeks

Table 18. Concentration of glycogen granules in the cytoplasm of the glandular epithelial cells of the sweat glands of the various body areas at various ages (values represent the concentration of glycogen as indicated below*)

	Birth	Age in weeks											
		1	2	3	4	6	8	10	12	16	20	24	28
Interscapular	5	10	0	0	0	0	0	0	0	0	0	0	0
Front foot pad	20	20	30	20	0	0	5	5	5	0	0	0	0
Sacral	0	0	0	0	0	0	10	0	10	0	0	0	0
Hind foot pad	20	20	20	20	10	10	10	10	5	5	0	5	0
Lip	0	0	0	0	0	a							
Vulva	0	0	0	0	0	a							

* 5 - Very slight
 10 - Slight
 20 - Moderate
 30 - Intense

^aMaterial was not collected from the lip and vulva above the age of 4 weeks

Table 19. Distribution of alkaline phosphatase in the sweat glands of interscapular area and foot pad at various ages (values represent the concentration of alkaline phosphatase as indicated below*)

	Birth	Age in weeks											
		1	2	3	4	6	8	10	12	16	20	24	28
Interscapular													
Myoepithelial cells	30	30	30	40	20	30	20	30	30	30	30	20	20
Secretory cell nuclei	20	20	20	30	10	20	10	20	20	20	20	10	10
Secretory cytoplasm	0	0	0	0	0	0	0	0	0	0	0	0	0
Foot pad													
Myoepithelial cells	30	20	30	20	20	30	20	30	20	20	20	20	20
Secretory cell nuclei	20	10	20	10	30	30	30	20	20	20	20	30	30
Secretory cytoplasm	10	0	0	0	0	0	0	0	0	0	0	0	0

*10 - Slight
 20 - Moderate
 30 - Intense
 40 - Very intense

apocrine glands than in the merocrine glands. The reaction for both glycogen and alkaline phosphatase in the merocrine glands was irregular or spotty. Fig. 51 shows the alkaline phosphatase reaction in the merocrine gland tubules. Fig. 52 shows a picture of typical merocrine glands stained with hematoxylin and eosin.

E. Sebaceous Glands

Table 20 shows the size of sebaceous glands at the various ages. The size of the sebaceous glands in the interscapular region varies from 30 to 50 microns to 80 to 250 microns with a gradual increase occurring with the increase in age. In the paraumbilical region, this correlation with the increase in age was not apparent. The largest sebaceous glands were observed at the muco-cutaneous junctions of the lips, vulva, and eyelids.

Alkaline phosphatase was observed quite consistently in the nuclei and cytoplasm of the peripheral cells of the sebaceous glands as shown in Fig. 53. The central cells reacted only in their nuclei, from a slight to a moderate degree.

Without exception, there was no glycogen observed in sebaceous glands in any of the tissue examined in this work. Fig. 54 shows a picture of Meibomian gland of the eyelid,

Table 20. Comparative size of sebaceous glands in the dermis of the skin of various body areas at various ages (values represent measurements with eyepiece micrometer, expressed in microns)

	Birth	Age in weeks											
		1	2	3	4	6	8	10	12	16	20	24	28
Interscapular													
Largest	50	90	45	40	60	80	110	60	115	160	70	140	250
Smallest	30	50	35	35	20	25	70	30	50	90	70	40	80
Paraumbilical													
Largest	45	100	40	45	70	40	80	60	110	100	80	60	50
Smallest	40	40	35	40	18	20	40	30	78	38	60	45	33
Lip margin	270	310	180	180	270	a							
Vulva or prepuce	350	180	200	300	200	a							

^aMaterial was not collected from the lip and vulva above the age of 4 weeks

Table 21. Distribution of alkaline phosphatase in the sebaceous glands of the dermis of the skin of the sacral region at various ages (values represent degree of concentration of reaction as shown below*)

	Birth	Age in weeks											
		1	2	3	4	6	8	10	12	16	20	24	28
Nuclei of peripheral cells	30	20	30	10	30	30	30	30	20	30	40	40	30
Cytoplasm of peripheral cells	0	10	0	0	10	0	10	10	0	0	10	20	0
Nuclei of central cells	10	10	10	10	10	10	10	10	10	10	20	20	10
Cytoplasm of central cells	0	0	0	0	0	0	0	0	0	0	0	0	0

*10 - Slight
 20 - Moderate
 30 - Intense
 40 - Very intense

which is a large modified sebaceous gland.

F. Arrector Pili Muscles

The largest arrector pili muscles were observed in the sacral and interscapular regions. The arrector pili muscles of the skin of the ventral surfaces of the body were found with difficulty and were very small and indistinct, Table 22.

The arrector pili muscles showed a slight reaction for alkaline phosphatase, only in the nuclei, with no correlation with age as shown on Table 23. Glycogen was observed in the cytoplasm of the smooth muscle cells of the arrector pili muscles from all areas and in all ages. Fig. 55 and Fig. 43 show pictures of glycogen in the arrector pili muscles.

Table 22. Size of arrector pili muscles in the dermis of the skin of various body areas at various ages (values represent measurements taken with an eyepiece micrometer, expressed in microns)

	Age in weeks												
	Birth	1	2	3	4	6	8	10	12	16	20	24	28
Interscapular													
Largest	40	30	15	20	40	15	45	70	40	120	50	140	115
Smallest	10	10	9	11	18	9	19	38	15	44	31	42	62
Paraumbilical	*	-	-	-	-	-	-	7	-	-	-	-	-

* - indicates that no arrector pili muscle was found in the section examined for the age and area

Table 23. Distribution of alkaline phosphatase and glycogen in the arrector pili muscle of the dermis of the skin of the sacral region at various ages (values represent degree of reaction as shown below*)

	Age in weeks													
	Birth	1	2	3	4	6	8	10	12	16	20	24	28	
Glycogen	10	20	30	20	20	20	20	30	10	20	10	10	10	
Alkaline phosphatase														
Nuclei	5	5	5	0	10	10	10	10	0	10	10	10	0	
Cytoplasm	0	0	0	0	0	0	0	0	0	0	0	0	0	

* 5 - Very slight
 10 - Slight
 20 - Moderate
 30 - Intense

V. DISCUSSION

A. Epidermis

Clear cells in the epidermis have been reported in the rat and man. Andrew and Andrew (1949) theorize that the clear cells are lymphocytes, which migrate into the epidermis, where they differentiate into epidermal cells. Andrew and Andrew (1954) classified cells which were not typical epidermal cells into three groups: clear cells, lymphocytes, and intermediate cells. The clear cells observed in this work on the skin of dogs did not conform with their description of any one of the three groups. The clear cells observed in this work on dog skin contained nuclei which stained intensely basophilic and they were observed in the process of cell division, especially telophase. Since mitotic figures in the epidermis of rat and human skin have been illustrated by Andrew and Andrew (1954) and Rothman (1954) as cells with transparent cytoplasm and dark staining nuclear material in various stages of cell division, all of the clear cells observed in canine skin in this work were regarded as representing mitotic figures.

The mitotic cells in this study were observed in the stratum cylindricum, for the most part, rather than in the stratum spinosum, as was reported for the human scalp by

Thuringer (1924). Thuringer and Cooper (1950) reported that there was an increase in mitoses with advancing age and the majority of mitotic figures were in the stratum spinosum. Cooper and Schiff (1938) presented evidence that mitotic rate is higher at night and lower in the day time in human skin. In the dog skin examined in this study, the rate of mitosis was higher in the thick skin of the planum nasale and foot pad than in the thin skin. No attempt was made to study any difference in mitotic rate at night or in the day time and no correlation was evident between mitotic activity and age.

Another theory on the clear cells was cited by Ham (1953). He cited the work of Masson (1948, 1935) and Becker (1942) who postulate that clear cells are of neural crest origin and that, with the proper stimulation, they manufacture melanin pigment.

Bullough and Eisa (1950) correlated the diurnal variation in mitotic activity with a corresponding variation in tissue glycogen in the mouse. Bradfield (1951) postulated that glycogen is necessary in the epidermal cells to provide the energy for the synthesis of keratin. Glycogen has been reported in the epidermis of man by Montagna et al. (1952) and Scothorne and Scothorne (1953). Wislocki et al. (1951) reported the occurrence of glycogen in the mucous membrane and skin of the monkey and Tribby (1943) reported glycogen in the

vaginal epithelium of the guinea pig. Glycogen was observed in the mucous membranes of the dogs studied in this work in great quantities. Very small quantities of glycogen were observed in the epidermis of the thin skin. These observations conform to the findings of Montagna et al. (1952) and Tribby (1943) in primates. It was noted that the thick skin of the planum nasale and the foot pads contained more glycogen and alkaline phosphatase than the thin skin. This would tend to indicate that the concentration of glycogen and alkaline phosphatase is greatest in the areas of epidermis where there is the greatest mitotic activity.

Very little alkaline phosphatase was found in the epidermis of the thin skin of the dog skin studied. This agrees with the findings of Bourne and MacKinnon (1943), who observed slight alkaline phosphatase activity in the stratum granulosum of guinea pig skin.

B. Dermis

The development of the dermis followed a definite pattern. Coinciding with a decrease of reticular fibers, there was an increase in the size of the bundles of collagenous fibers, with a concurrent decrease in the number of nuclei. This has been observed in other species. Yuditskaya (1947) reported that the only fibrous protein

recovered from cattle embryo skin was reticulin. Gross (1950) reported an overwhelming predominance of argyrophilic reticulin in the newborn rat with a gradual transition to typical collagen with aging. This evidence supports the theories that reticulin is an early developmental stage of collagen or that reticulin is basically collagen. Fig. 33 shows that the reticular fibers appear to be continuous with collagenous bundles. This was observed by Odland (1950) in human epidermis. The observation that alkaline phosphatase was more plentiful in fibroblast nuclei in the younger skin would tend to indicate that alkaline phosphatase is related to collagen formation. Gold and Gould (1951) found this to be true in healing wounds. Robertson *et al.* (1950) on the contrary were unable to demonstrate alkaline phosphatase in artificially produced areas of collagen formation.

The elastic fibers observed in this work were not as plentiful as those described in the adult human skin by Dick (1947). In the skin of children Dick reported few elastic fibers. The observations of this work on the dog agree with Dick's that elastic tissue of the dermis increases with normal growth and development.

It was observed that the dermis increased in thickness with an increase in age. This was accompanied by an increase in the number and size of the collagenous bundles. Since the reticular fibers and fibroblasts were most numerous

at birth and decreased in number with an increase in age, it is logical to conclude that the reticular fibers are developmentally related to collagenous fibers. The observation that collagenous fibers were continuous with reticular fibers supports this conclusion.

C. Hair Follicles

Considerable information is available on the hair cycle of rat, mouse, ferret, and human skin. Rothman (1954) divided the hair cycle into three stages: (1) the anagen stage, the phase of active proliferation; (2) the catagen stage, a transitional phase, characterized by cessation of active proliferation and by club hair formation; and (3) the telogen (final) or resting stage. After this stage, the hair cycle starts all over again. Chase and co-workers (1953) described variations in the thickness of the epidermis and corium which are directly related to the hair cycle in the mouse. The development of the germ of the hair follicle in rat embryos was reported by Fraser (1928). Butcher (1934) found the hair cycle of the rat to be a 35-day cycle with 17 days of growth and 17 days of rest. He found that five days after birth, the first hair coat comes in and at 35 days after birth the second hair coat comes in. The new hair does not push out the old, so two hairs remain in

the follicle. At 84 days after birth, he reported three hairs may be observed in a follicle. There are never more than three hairs in a follicle of rat skin.

Apparently the hair cycle of the dog skin is much different because of the compound nature of the follicle and the seasonal manner in which the dog sheds its hair coat. One could postulate that instead of the first hair becoming detached and a new hair bulb developing as occurs in the rat, that in the dog, the first hair remains attached and actively growing even after the second hair develops. The second hair develops as a bud or a branch from the main follicle, resulting in two hairs being present in the follicle. Then as the age increases and additional hairs are added, the follicle complex becomes larger until the condition of 28 weeks is reached, where there are 7 to 10 hairs embraced in a single hair follicle orifice.

Since no resting follicles were observed in the material studied, it is assumed that during the period from birth to 28 weeks of age the hair follicle of the dog does not make a complete cycle. Bissonnette (1935) reported that in the ferret the hair cycle is related to the anterior hypophysis and to light cycles. He found that the spring loss of winter coat in ferrets occurs five to six weeks after the beginning of estrous or two to five days before parturition. Hypophysectomy was followed by loss of some

hair but lead to suppression of the sexual cycle and hair cycle.

None of the dogs used in this study were observed to show any manifestations of estrous. If the hair cycle is related to the estrous cycle or sexual maturity of the dog, during shedding, one would expect to find the resting follicles in the skin after estrous. This would explain why no resting follicles were observed in this work. Additional research on the hair cycle of sexually mature dogs is necessary before definite conclusions can be made.

Histochemical studies of human skin have been made by Montagna, Chase, and Lobitz (1952), in which they found glycogen to be most abundant in the external sheath of active hair follicles. The only other regions of the follicle in which they found glycogen, were the medulla and the cuticle cells of the cortex. Usually, the internal sheath, cortex, and matrix cells of the hair bulb contained none. Johnson and Bevelander (1946) studied the distribution of alkaline phosphatase and glycogen in the developing hair follicle of the rat. They found both alkaline phosphatase and glycogen were present in the primitive hair bud. During the later stages of dif-

ferentiation and growth, they observed that the spatial relations between phosphatase and glycogen correlated well with the path of glucose entry into the tissues. Johnson, Butcher, and Bevelander (1945) studied the distribution of alkaline phosphatase in the cyclic growth of the rat hair follicle. They found the enzyme was present to a very slight degree in the early epithelial bud, becoming very abundant in the mesodermal papilla as the follicle matured and elaborated the hair. With the tapering off of the cellular activity the quiescent period of the hair cycle was characterized by a negligible amount of alkaline phosphatase. Bollinger and McDonald (1949) investigated the glycogen in skin and hair of man, sheep, rabbit, and phalanger. They observed granules in the outer root sheath, which stained selectively with periodic acid treatment and fuchsin sulphite. Hardy (1952) studied the histochemistry of hair follicles in the mouse and reported the presence of glycogen in the outer root sheath and alkaline phosphatase in the dermal papilla of the active hair follicle. The findings in this work show that the distribution of glycogen and alkaline phosphatase in the dog hair follicle is similar to that reported by Hardy (1952) in the mouse.

Alkaline phosphatase was present in the dermal papillae of all hair follicles observed in this study. According to Johnson et al. (1945) this indicates that these follicles were in an active growing phase rather than a quiescent phase.

D. Sweat Glands

Montagna, Chase, and Lobitz (1952) reported that in eccrine (merocrine) sweat glands of human skin, some secretory cells are rich in glycogen while others are not.

Bunting, Wislocki, and Dempsey (1948) found that glycogen was abundant in the secretory tubules of the eccrine glands, but has not been found in apocrine glands.

Fisher and Glick (1947) reported alkaline phosphatase activity in the endothelial cells and sweat glands of human skin. They observed that the enzyme appeared to be concentrated at the cell walls and in the nuclei.

The observations made on dog skin that the merocrine glands of the foot pads contain the greatest concentration of glycogen and the apocrine glands contained only traces agrees with the findings of Montagna, Chase, and Lobitz (1952) and Bunting, Wislocki, and Dempsey (1948) in human skin.

In dogs of all ages, alkaline phosphatase activity was observed in the nuclei of the secretory cells and the nuclei and myoepithelial cells of both merocrine and apocrine glands. Since phosphatase indicates cellular activity, this would lead to the conclusion that the sweat glands are actively secreting from the time of birth through 28 weeks of age.

E. Sebaceous Glands

Location of alkaline phosphatase in the sebaceous glands of the dog agrees with that reported by Montagna and Noback (1947) in the rat. The size of the sebaceous glands on the dorsal skin increased with age but the alkaline phosphatase activity remained constant for all ages.

F. Technique for Acid and Alkaline Phosphatase

The histochemical method for alkaline phosphatase, originally devised by Gomori (1939) and by Takamatsu (1939) has been widely employed in histology. The technique is based on the principle that if sections are incubated with glycerophosphate at an alkaline reaction in the presence of Ca ions, the phosphate ions liberated will be precipitated at the site of formation as insoluble Ca phosphate. The

latter is then transformed in a second step into black cobalt sulfide. With this method, the amount and distribution of phosphatase have been observed to change in a number of physiological and pathological states. The method seems to be of value since it provides an index by which the activity of the tissues may be measured. Danielli (1953), Martin and Jacoby (1949), and Gomori (1951) have made critical studies of the phosphatase technique. These workers suggest that nuclear staining in areas of high activity is an artefact due to the secondary adsorption of Ca phosphate. The evidence for this is that the Azo-dye methods, for the demonstration of alkaline phosphatase, do not show any alkaline phosphatase in cell nuclei. Martin and Jacoby (1949) make the conclusion that a positive result shows the presence of the enzyme, but a negative result does not necessarily demonstrate its absence. They also felt that a positive reaction indicates the presence of enzymes, but that it does not necessarily give its precise location and may even mask histochemically inherently negative structures.

The original histochemical method for acid phosphatase utilizes the hydrolysis of glycerophosphate at pH 5 in the presence of lead ions. Fixation in cold acetone or alcohol have been used (Dempsey and Deane, 1946). It is agreed by most authors that the results of this technique are not

nearly so satisfactory or consistent as those of the method for alkaline phosphatase.

It is recognized that the technique for the demonstration of acid and alkaline phosphatase have definite limitations and this causes considerable doubt as to the value of conclusions that can be drawn from results obtained from these histochemical methods.

The failure to demonstrate the presence of acid phosphatase in this work by no means is enough evidence to conclude that there is no acid phosphatase in canine skin. The presence of alkaline phosphatase in the nuclei of many areas reported in this work may be the results of diffusion artefacts. It is difficult or impossible to come to any conclusions in regard to the significance of these results. The findings here presented on the histochemistry of canine skin compare favorably with results reported on human skin using the same technique. More research should be done on the histochemistry of canine skin so that a more definite insight may be developed into the nature of the intermediary metabolism taking place at cell membranes and boundaries.

VI. SUMMARY

1. Skin samples from 10 or 12 different areas from 13 normal dogs, ranging in age from birth to 28 weeks, were studied microscopically. A total of 140 skin areas were studied.
2. Observations have been made on the morphology, location of glycogen, and distribution of alkaline phosphatase in normal canine skin at various ages.
3. No acid phosphatase was observed in any part of the skin at any age.
4. From birth to 28 weeks alkaline phosphatase was observed in greatest quantities in the connective tissue hair papillae, nuclei, and cytoplasm of cells of the mucous membranes, peripheral cells of sebaceous glands, myo-epithelial cells of sweat glands, nuclei, and cytoplasm of the cells at the depths of epidermal pegs of foot pads and planum nasale, fibroblasts and capillary endothelial cells of the dermal papillae of foot pads and planum nasale, nuclei of the hair matrix cells, and nuclei of secretory cells of the sweat glands.
5. At all ages alkaline phosphatase was found to be present in lesser amounts in the nuclei of the smooth muscle cells of arrector pili muscles, nuclei of the central sebaceous gland cells, nucleoli of spinosum cells and

- keratohyalin granules of the epidermis of the hairy skin.
6. The fibroblasts and capillary endothelial cells of the dermis of the hairy skin contained alkaline phosphatase only during the first three weeks.
 7. Glycogen was observed in greatest quantities in the cytoplasm of the epithelial cells of the mucous membranes and middle third of the outer root sheath in all ages studied.
 8. The next greatest quantity of glycogen was observed in the cytoplasm of the secretory cells of the merocrine glands of the foot pads and arrector pili smooth muscle cells.
 9. During the first three weeks glycogen was present in the foot pad and planum nasale spinosum cells. A few very fine glycogen granules were observed around the hair follicle orifices in the hairy skin epidermis in all ages.
 10. No glycogen was observed in the sebaceous glands or connective tissue of the dermis. A trace of glycogen was observed in the secretory cells of the apocrine glands and hair matrix and hair papillae in very young material.
 11. The morphology and thickness of the epidermis of the hairy skin was observed to change very little, whereas

the thickness of the epidermis of the foot pads and planum nasale increase steadily with an increase in age.

12. A greater number of mitotic clear cells were observed in the epidermis of the foot pads and planum nasale than in the epidermis of the hairy skin. No correlation was apparent between age and number of mitotic figures in the epidermis per section.
13. Epidermal pegs were not observed in the hairy skin, but they were found to be very extensive in the mucous membranes and foot pads and planum nasale.
14. Thickened papilla-like areas of epidermis were observed in various parts of the skin at all ages. These were called epidermal papillae.
15. With an increase in age, the dermis was observed to increase in thickness. This was accompanied by an increase in the number and size of the elastic fibers and collagenous bundles.
16. Reticular fibers and fibroblasts were observed to be most numerous at birth and decreased in number with an increase in age.
17. Reticular fibers were observed interdigitating between the basal cells of the epidermis and appeared to be continuous with collagenous fibers of the dermis. Fibroblasts were also observed between the basal cells

of the epidermis.

18. The hair follicles were observed to develop from a simple form (each follicle embracing a single hair) at birth to a compound form (each follicle embracing 7-10 hairs) at 28 weeks of age. The additional hairs developed from buds off the original follicle which separated deeply into auxiliary follicles which united superficially with the main follicle.
19. Immature, developing hair follicles were observed on the margin of the ear, during the first week.
20. No resting follicles were observed in any of the skin areas examined.
21. Histological evidence of secretory activity was observed in merocrine and apocrine glands of areas studied at all ages.
22. The excretory ducts of the apocrine glands were observed emptying into the hair follicles above the level of the sebaceous gland.
23. It was observed that sebaceous glands in the interscapular area tended to become larger with an increase in age. The largest sebaceous glands were observed around the mucocutaneous junctions.
24. It was observed that the arrector pili muscles of the interscapular area tended to increase in width with

an increase in age. The largest arrector pili muscles were observed in skin of the dorsal part of the body.

VII. CONCLUSIONS

1. Alkaline phosphatase is present in canine skin in areas of greatest cellular activity.
2. Alkaline phosphatase and glycogen are located in areas of canine skin comparable with those reported in human and rat skin.
3. Clear cells are present in the stratum cylindricum of the epidermis of canine skin and probably represent mitotic figures.
4. The rate of mitosis is greater in the epidermis of the foot pads and planum nasale than in the hairy skin.
5. Epidermal papillae are normally present in the epidermis of the hairy skin of the dog.
6. There is no developmental increase in the thickness of the epidermis in the hairy skin of the dog between birth and 28 weeks of age.
7. There is a normal increase in the thickness of the epidermis of the foot pads and planum nasale and the dermis of all body areas between birth and 28 weeks of age.
8. The hair follicle of the dogs studied developed from a simple follicle at birth to a compound follicle at maturity.
9. One entire hair cycle was not completed during the first six months of the life of the dogs studied.

10. Additional research should be done on the hair follicle of the dog before definite conclusions may be made concerning the hair cycle.
11. At the time of birth the sweat glands of canine skin are well developed and functional.
12. Reticular fibers are closely related to collagenous fibers, developmentally and morphologically.
13. At the time of birth the sebaceous glands of canine skin are well developed and functional.

VIII. LITERATURE CITED

- Andrew, W. and Andrew, N. V. 1949. Lymphocytes in the normal epidermis of the rat and man. *Anat. Rec.* 104: 217-241.
- _____ and _____ 1954. Lymphocytes in normal epidermis of young, older middle-aged, and senile rats. *J. Geront.* 9:412-420.
- Aoki, T. and Wada, M. 1951. Functional activity of the sweat glands in the hairy skin of the dog. *Science* 114:123-124.
- Becker, S. W. 1942. Cutaneous melanoblasts as studied by the paraffin dopa technique. *J. Invest. Derm.* 5:463. (Original article not available for examination; cited by Ham.)
- Bensley, R. R. and Bensley, S. H. 1938. Handbook of histological and cytological technique. University of Chicago Press. Chicago, Ill.
- Billingham, R. E. 1948. Dendritic cells. *J. Anat.* 82: 93-109.
- Bissonnette, T. H. 1935. Relations of hair cycles in ferrets to changes in anterior hypophysis and to light cycles. *Anat. Rec.* 63:159-168.
- Bolliger, A. and McDonald, N. D. 1949. Histological investigation of glycogen in skin and hair. *Aus. J. Exp. Biol. & Med.* 27:223-228.
- Bourne, G. and MacKinnon, M. 1943. The distribution of alkaline phosphatase in various tissues. *Quart. J. Exp. Physiol.* 32:1.
- Bradfield, J. R. G. 1951. Glycogen in vertebrate epidermis. *Nature (London)* 167:40-41.
- Bullough, W. S. and Eisa, E. A. 1950. The diurnal variations in the tissue glycogen content and their relation to mitotic activity in the adult male mouse. *J. Exp. Biol.* 27:257-263.

- Bunting, H., Wislocki, G. B. and Dempsey, E. W. 1948. The chemical histology of human eccrine and apocrine sweat glands, *Anat. Rec.* 100:61-78.
- Butcher, E. O. 1934. The hair cycles in the albino rat. *Anat. Rec.* 61:5-19.
- Chase, H. B., Montagna, W. and Malone, J. D. 1953. Changes in the skin in relation to the hair growth cycle. *Anat. Rec.* 116:75-81.
- Claushen, A. 1933. Mikroskopische Untersuchungen über die Epidermalgebilde am Rumpfe des Hundes mit besonderer Berücksichtigung der Schweissdrüsen. *Anat. Anz.* 77: 81-97.
- Cooper, Z. K. and Schiff, A. 1938. Mitotic rhythm in human epidermis. *Proc. Soc. Exp. Biol. & Med.* 39:323-324.
- Danielli, J. F. 1953. *Cytochemistry, a critical approach.* John Wiley and Sons Inc. New York, N.Y.
- Dempsey, E. W. and Deane, H. W. 1946. The cytological localization, substrate specificity and pH optima of phosphatases in the duodenum of the mouse. *J. Cell. & Comp. Physiol.* 27:159-179.
- Dick, J. C. 1947. Observations on the elastic tissue of the skin. *J. Anat.* 81:201-211.
- Ellenberger, W. 1906. *Handbuch der Vergleichenden Mikroskopischen Anatomie der Haustiere.* Vol. 1. Paul Parey. Berlin.
- _____ and Baum, H. 1943. *Handbuch der Vergleichenden Anatomie der Haustiere.* 18th ed. Berlin, Julius Springer.
- Epling, G. P. 1953. The anatomy of the skin. Chapter 10. *Canine Medicine.* American Veterinary Publications Inc. Evanston, Ill.
- Fisher, I. and Glick, D. 1947. Localization of alkaline phosphatase in normal and pathological human skin. *Proc. Soc. Exper. Biol. & Med.* 66:14-18.
- Foot, N. C. and Menard, M. C. 1927. A rapid method for silver impregnation of reticulum. *Arch. Path.* 4:211-214.

- Fraser, D. A. 1928. The development of the skin of the back of the albino rat until the eruption of the first hairs. *Anat. Rec.* 38:203-223.
- Fuchs, F. 1934. Mikroskopische Untersuchungen über die Epidermalgebilde an Kopf und Gliedmassen des Hundes. Diss. Tierärztliche Hochschule. (Original not available for examination; abstracted in *Biol. Abst.* 1893. 1936.)
- Gair, R. 1928. Die Wuchsformen des Haarkleides bei Haustieren nach Untersuchungen beim Hunde. *Zeitschr. Tierzucht u. Zuchtungsbiol.* 11(1):57-88. (Original not available for examination; abstracted in *Biol. Abst.* 2641. 1931.)
- Gold, N. I. and Gould, B. S. 1951. Collagen fiber formation and alkaline phosphatase. *Arch. Biochem.* 33:155-164.
- Gomori, G. 1939. Microtechnical demonstration of phosphatase in tissue sections. *Proc. Soc. Exp. Med.* 42:28-36.
- _____ 1951. Alkaline phosphatase of cell nuclei. *J. Lab. & Clin. Med.* 37:526-531.
- _____ 1952. Microscopic histochemistry, principles and practice. University of Chicago Press. Chicago, Ill.
- Gross, J. 1950. A study of the aging of collagenous tissue of rat skin with the electron microscope. *Am. J. Path.* 26:708.
- Gurlt, E. F. 1835. Vergleichende Untersuchungen über die Haut des Menschen und der Haus-Säugethiere, besonders in Beziehung auf die Absonderungsorgane des Haut-talges und des Schweisses. *Arch. F. Anat., Physiol. u. Weissensch. Med.* 1835:399-418.
- Guyer, M. F. 1936. Animal micrology, practical exercises in zoological micro-technique. 4th ed. University of Chicago Press. Chicago, Ill.
- Ham, A. W. 1953. Histology. 2nd ed. J. B. Lippincott Co. Philadelphia, Penn.

- Hansen, A. E., Holmes, S. G. and Wiese, H. F. 1950. Histologic features of the skin of dogs on a low fat diet. *Fed. Proc.* 9:332.
- _____, Sinclair, J. G. and Wiese, H. G. 1954. Sequence of histologic changes in skin of dogs in relation to dietary fat. *J. Nutrition* 52:541-554.
- Hardy, M. H. 1952. The histochemistry of hair follicles in the mouse. *Am. J. Anat.* 90:285-329.
- Hildebrand, M. 1952. The integument in Canidae. *J. Mammal.* 33:419-428.
- Johnson, E., Andrews, F. N. and Shrewsbury, C. L. 1943. The preparation of muscular tissues for histological study. *J. Animal Sci.* 2:244-250.
- Johnson, P. L. and Bevelander, G. 1946. Glycogen and phosphatase in the developing hair. *Anat. Rec.* 95:193-220.
- _____, Butcher, E. P. and Bevelander, G. 1945. The distribution of alkaline phosphatase in the cyclic growth of the rat hair follicle. *Anat. Rec.* 93:355-361.
- Mallory, F. B. 1938. Pathological technique, a practical manual for workers in pathological histology. W. B. Saunders Co. Philadelphia, Penn.
- Martin, B. F. and Jacoby, F. 1949. Diffusion phenomenon complicating the histochemical reaction for alkaline phosphatase. *J. Anat.* 83:351-363.
- Masson, P. 1935. Melanoblasts et cellules de Langerhans. *Soc. Derm. Paris, Reunion dermat. de Strasbourg.* 1112. (Original not available for examination; cited by Ham.)
- _____. 1948. Pigment cells in man, in the biology of the melanomas. *Spec. Pub., New York Acad. Sci., IV:* 15. (Original not available for examination; cited by Ham.)
- Maximow, A. A. and Bloom, W. 1952. A text book of histology. 6th ed. W. B. Saunders Co. Philadelphia, Penn.
- Meijere, J. C. H. de. 1894. "Über die Haare der Säugethiere, besonders über ihre Anordnung. *Gegenbaur's Morph. Jahrb.* 21:312-424. (Original not available for examination; cited by Hildebrand.)

- Montagna, W., Chase, H. B. and Lobitz, W. C. Jr. 1952. Histology and cytochemistry of human skin, the distribution of glycogen in the epidermis, hair follicles, sebaceous glands, and eccrine sweat glands. *Anat. Rec.* 114:231-248.
- _____ and Noback, C. R. 1947. Histochemical observations on sebaceous glands of the rat. *Am. J. Anat.* 81:39-62.
- _____ and Parks, H. F. 1948. A histochemical study of the glands of the anal sac of the dog. *Anat. Rec.* 100:297-318.
- Muto, K. 1925. A histological study of the sweat glands of mammals. *Jap. Soc. Vet. Sci. J.* 4:6-7.
- Nielsen, S. W. 1953. Glands of the canine skin, morphology and distribution. *Am. J. Vet. Research* 14:448-454.
- Odland, G. F. 1950. The morphology of the attachment between the dermis and the epidermis. *Anat. Rec.* 108:399-414.
- Parks, H. 1950. Morphological and cytochemical observations on the circumanal glands of the dog. Ph. D. Thesis. Cornell University. Ithaca, N.Y. (Original not available for examination; cited by Trautmann and Fiebiger, translated edition.)
- Pearson, G. A. 1942. Eosin Y for tissues. *Am. J. Clin. Path.* 12:16 (Supp. 6)
- Robertson, W., Dunihue, F. W. and Novikoff, A. B. 1950. The metabolism of connective tissue: Absence of alkaline phosphatase in collagen fibers during formation. *Brit. J. Exper. Path.* 31:545-549.
- Rothman, S. 1954. *Physiology and Biochemistry of the skin.* University of Chicago Press. Chicago, Ill.
- Schaffer, J. 1924. Zur Einteilung der Hautdrüsen. *Anat. Anz.* 57:353-372.
- _____ 1930. Zur phylogese der Talgdrüsen. *Ztschr. f. Mikr. Anat. Forsch.* 22:579-590.
- Scothorne, R. J. and Scothorne, A. W. 1953. Histochemical studies on human skin autographs. *J. Anat.* 87:22-29.

- Sisson, S. and Grossman, J. D. 1953. The anatomy of the domestic animals. W. B. Saunders Co. Philadelphia, Penn.
- Speed, J. G. 1941. Sweat glands of the dog. *Vet. Jour.* 97:252-256.
- Takamatsu, H. 1939. Histologische und biochemische Studien über die phosphatase. *Transact. Soc. Path. Jap.* 29:429. (Original not available for examination; reviewed in *J. Cell. and Comp. Physiol.* 17:71. 1941.)
- Thuringer, J. M. 1924. Regeneration of stratified squamous cell epithelium. *Anat. Rec.* 28:31-38.
- _____ and Cooper, Z. K. 1950. The mitotic index of the human epidermis, the site of maximum cell proliferation and development of the epidermal pattern. *Anat. Rec.* 106:255.
- Trautmann, A. and Fiebiger, J. 1949. *Lehrbuch der Histologie und Vergleichenden Mikroskopischen Anatomie der Haus- saugtiere.* Paul Parey, Berlin. (Translated and revised by Robert E. Habel and Ernest L. Biberstein. Ithaca, N.Y. Comstock Pub. Associates. 1952.)
- Tribby, C. V. 1943. The intercellular lipin, mucoid, and glycogen of the vaginal epithelium of the guinea pig. *Anat. Rec.* 86:425-451.
- Varicak, T. 1941. Observations concerning the epidermis in domestic animals. *Vet. Archives.* 11:189. (Original not available for examination; abstracted in *Vet. Bull.* 18(1948):133.)
- Webb, A. J. and Calhoun, M. L. 1954. The microscopic anatomy of the skin of mongrel dogs. *Am. J. Vet. Res.* 15:274-280.
- Wislocki, G. B., Fawcett, D. W. and Dempsey, E. W. 1951. Staining of stratified squamous epithelium of mucous membranes and skin of man and monkey by the periodic acid-Schiff method. *Anat. Rec.* 110:359-375.
- Yuditskaya, A. I. 1947. The chemical nature of reticulín. *Biokhimiya* 14:97-101. (Original not available for examination; abstracted in *Chem. Abstr.* 43:6263. 1949.)

IX. ACKNOWLEDGMENTS

The writer wishes to express his appreciation and gratitude to Dr. R. Getty for his encouragement, suggestions, and counsel during this study; to Dr. J. G. Bowne for photographs taken of gross specimens and cooperation and assistance in obtaining specimen material from the dog colony of the Department of Anatomy; and to Mr. Louis A. Facto for the photomicrographs taken.

Appreciation is also expressed to the Gaines Division of General Foods Corporation, Kankakee, Illinois, for furnishing all the dog food for this work.

X. PHOTOGRAPHS

Fig. 1. Areas from which skin was studied

Fig. 1a. Lateral view

Fig. 1b. Ventral view

1. Interscapular area (dorsal shoulder region)
2. Front foot pad (metacarpal)
3. Sacral area (at base of tail)
4. Rear foot pad (metatarsal)
5. Paraumbilical area (ventral abdomen)
6. Tip of nose (planum nasale)
7. Base of teat (hairy margin)
8. Eyelid (upper)
9. Inside fold of flank (inguinal region)
10. External ear flap (pinna)
11. Margin of lip (upper)
12. Margin of vulva or prepuce

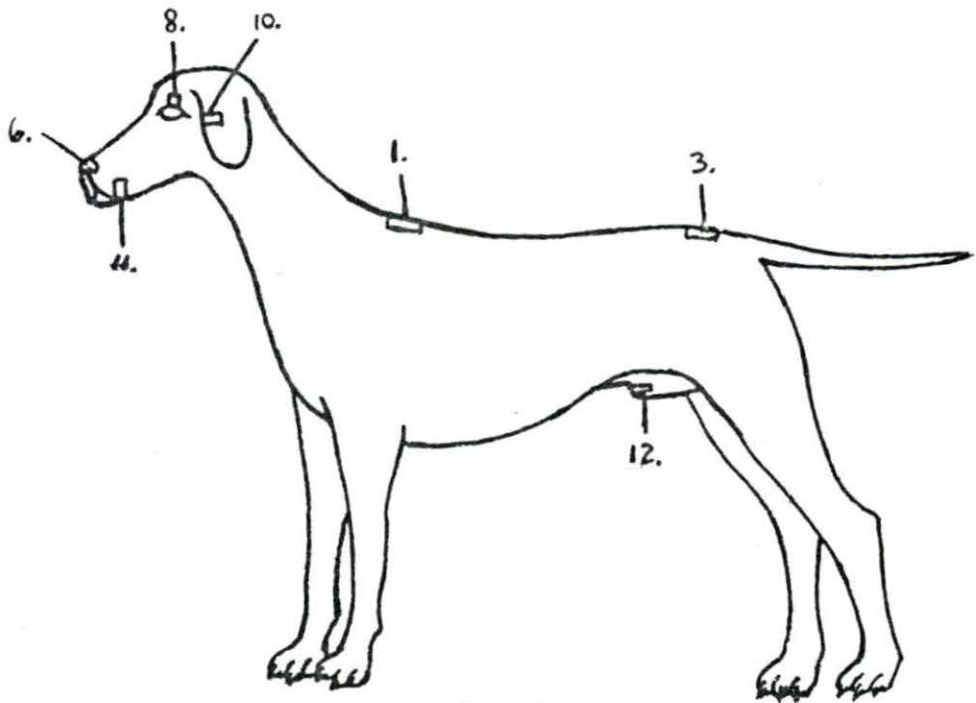


FIG. 1a

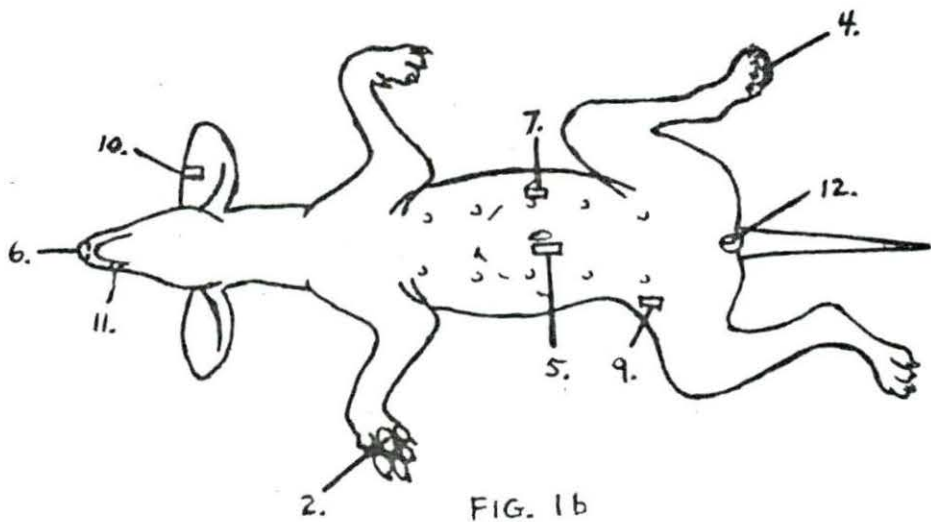


FIG. 1b

FIG. 1

Fig. 2. Nasal skin at birth - Section of skin from the planum nasale of a dog shortly after birth, fixed in formalin and stained with Harris' hematoxylin and eosin Y, 90X magnification; note the undulation of the basal layer of epithelial cells and the thickness of the epidermis as compared with Fig. 3

- a. Stratum corneum
- b. Stratum spinosum
- c. Stratum cylindricum
- d. Dermis
- e. Undulation of basal layer to form epidermal pegs

Fig. 3. Nasal skin at 28 weeks - Section of skin from the planum nasale of a dog 28 weeks of age, fixed in 10 per cent formalin and stained with Harris' hematoxylin and eosin Y, 90X magnification; note the thickness of the epidermis as compared to Fig. 2, for contrast between the thickness of the nasal epidermis of birth and 28 weeks of age

- a. Nucleated stratum corneum
- b. Stratum spinosum
- c. Stratum cylindricum
- d. Dermis
- e. Epidermal peg

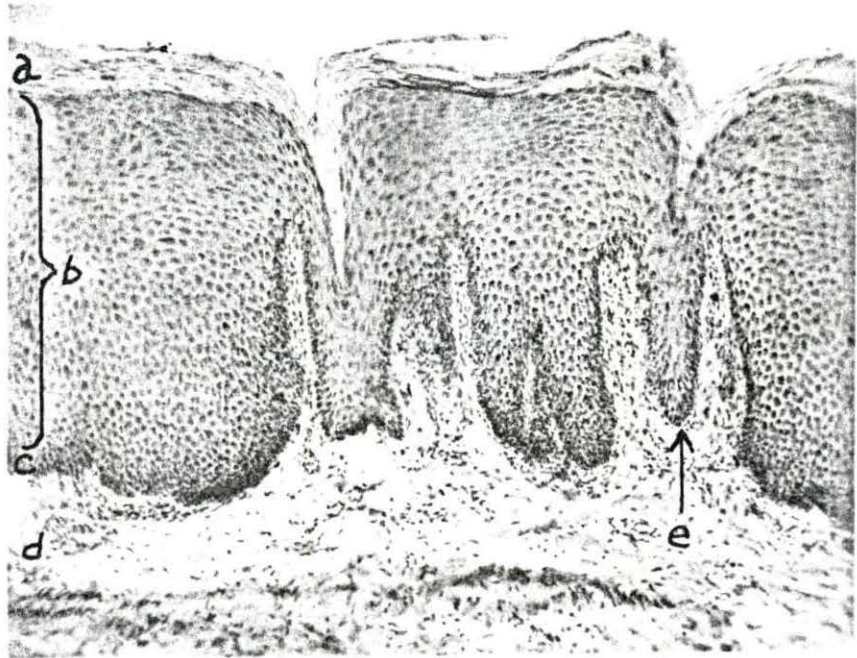
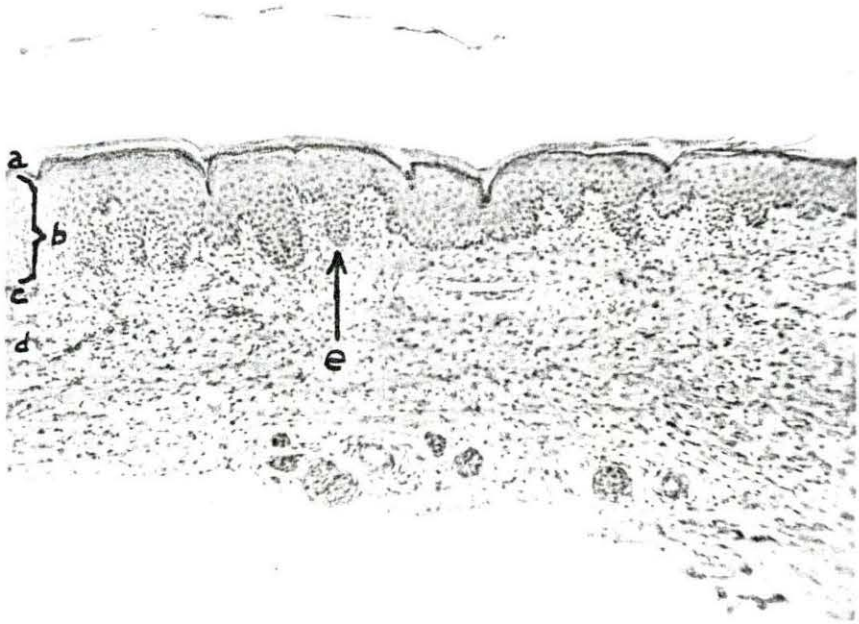


Fig. 4. Hairy skin at birth - Section of heavily haired skin from the interscapular area taken from a dog shortly after birth, fixed in 80 per cent alcohol and stained with Harris' hematoxylin and eosin Y, 35X magnification

- a. Epidermis
- b. Dermis
- c. Subcutis
- d. Hair follicle containing one hair

Fig. 5. Foot pad at birth - Section of skin from the front foot pad taken from a dog shortly after birth, fixed in 80 per cent alcohol and stained with Harris' hematoxylin and eosin Y, 35X magnification; sweat glands may be observed in the subcutaneous tissue

- a. Epidermis
- b. Dermis
- c. Subcutis
- d. Merocrine glands

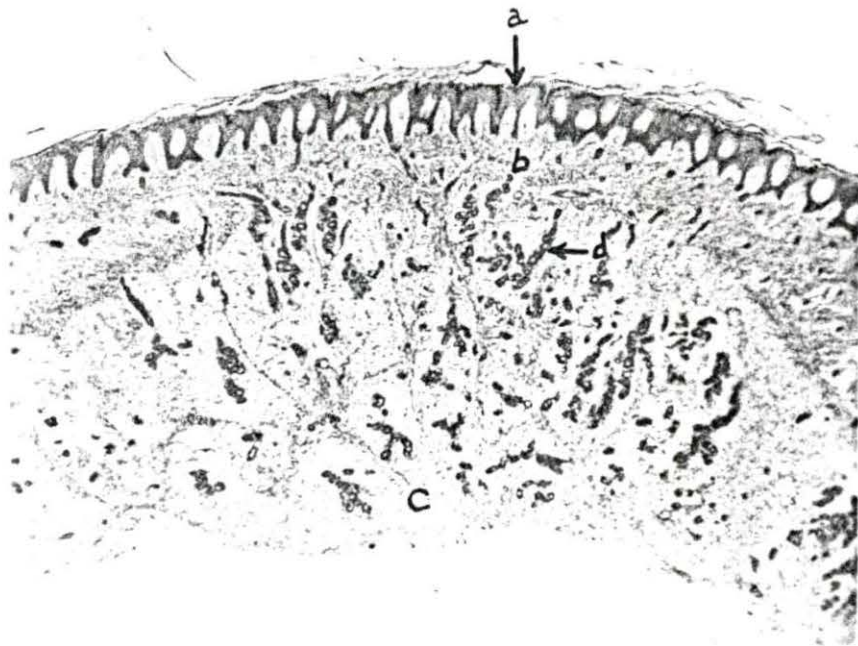
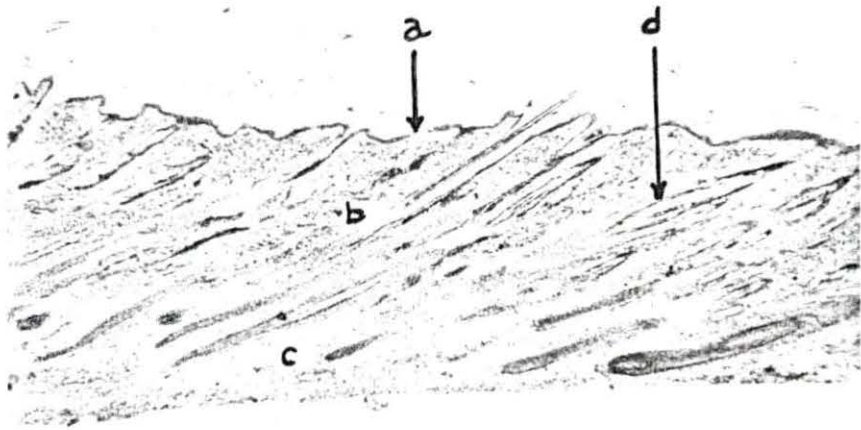


Fig. 6. Hairy skin at eight weeks - Section of heavily haired skin from the interscapular area of a dog eight weeks of age, fixed in 10 per cent formalin and stained with Harris' hematoxylin and eosin Y, 35X magnification

- a. Epidermis
- b. Dermis
- c. Subcutis
- d. Hair follicle containing three hairs

Fig. 7. Foot pad at eight weeks - Section of skin from the front foot pad of a dog eight weeks of age, fixed in 80 per cent alcohol and stained with Harris' hematoxylin and eosin Y, 35X magnification

- a. Stratum corneum and lucidum
- b. Stratum granulosum, spinosum and cylindricum
- c. Dermal papilla
- d. Merocrine sweat gland

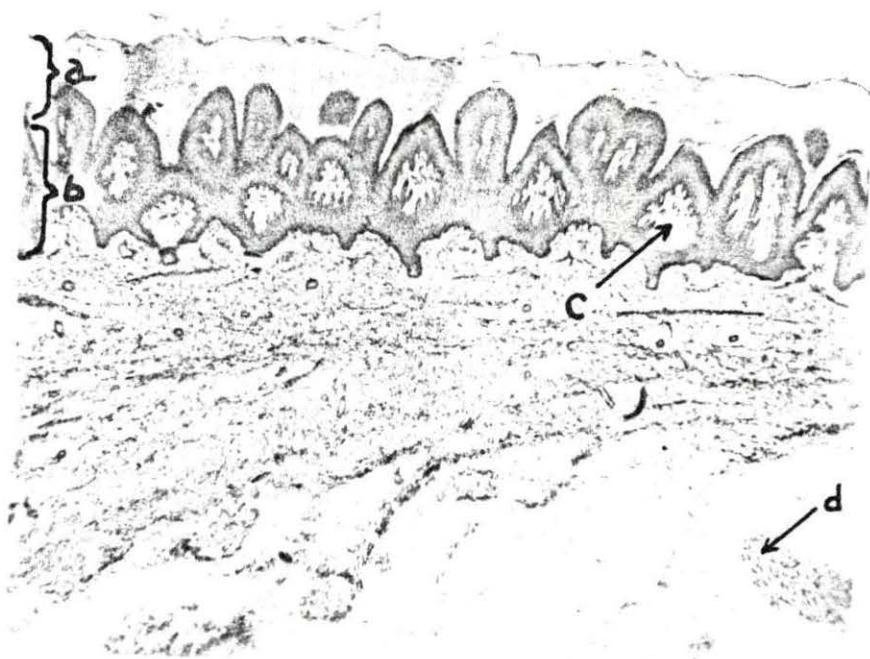



Fig. 8. Hairy skin at 28 weeks - Section of heavily haired skin from the interscapular area of a dog 28 weeks of age, fixed in 80 per cent alcohol and stained with Harris' hematoxylin and eosin Y, 35X magnification; notice that eight to ten hairs converge at the external follicle orifice

- a. Epidermis
- b. Dermis
- c. Subcutis
- d. Apocrine gland
- e. Sebaceous gland
- f. Follicle containing ten hairs

Fig. 9. Foot pad at 28 weeks - Section of skin from the front foot pad of a dog 28 weeks of age, fixed in 80 per cent alcohol and stained with Harris' hematoxylin and eosin Y, 35X magnification

- a. Stratum corneum
- b. Stratum lucidum
- c. Stratum granulosum
- d. Stratum spinosum
- e. Stratum cylindricum
- f. Dermis

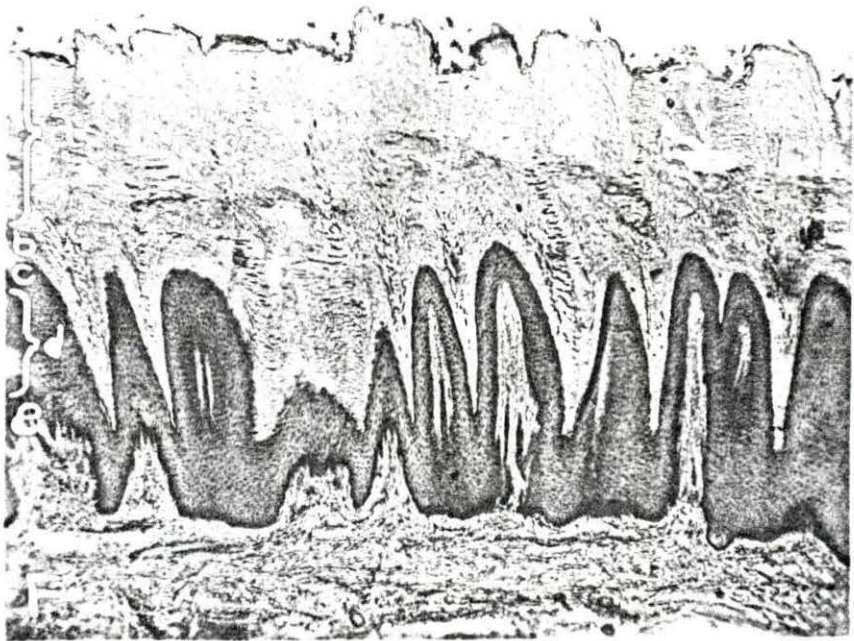
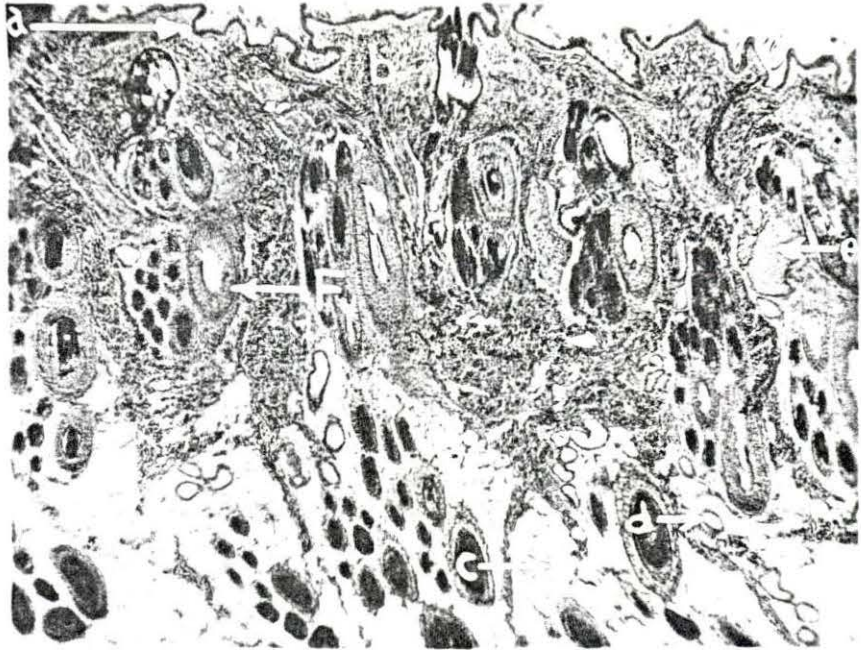


Fig. 10. Epidermal papilla - Picture of an epidermal papilla taken at 18X magnification from a mature dog

a. Epidermal papilla

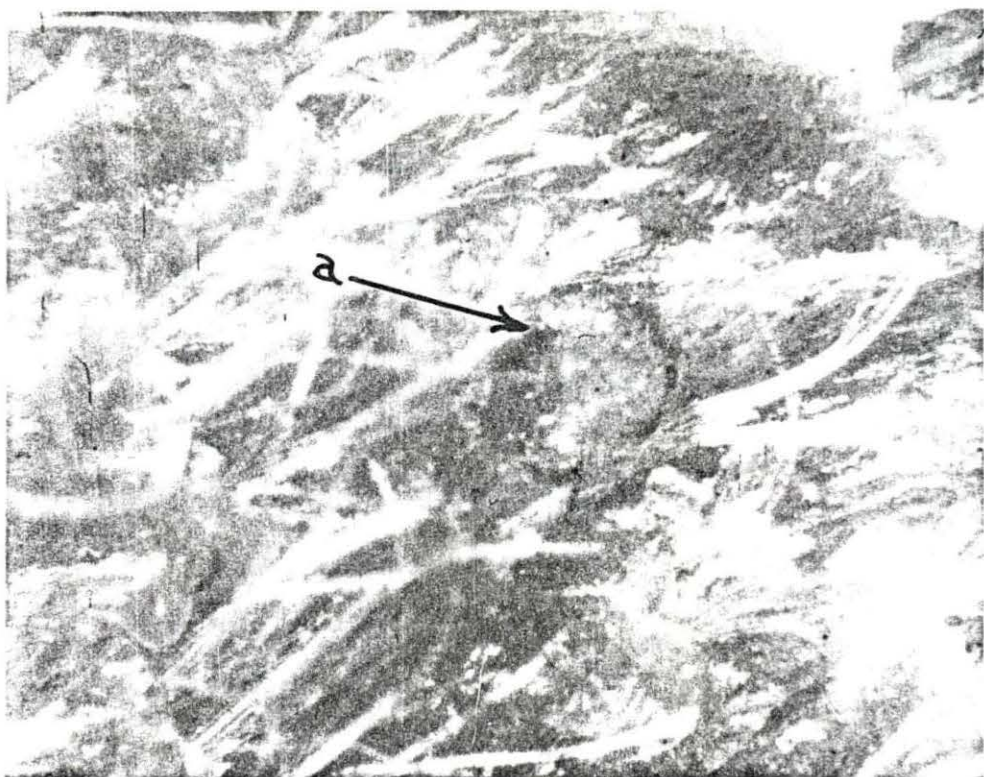


Fig. 11. Epidermal papilla - Section of skin from the interscapular region of a dog at the time of birth, fixed in 80 per cent alcohol and stained with Harris' hematoxylin and eosin Y, 470X magnification; it may be observed that the epidermis is thickened into a papilla-like formation in the center of the picture, the underlying dermis forms a core-like structure under this epidermal thickening

- a. Epidermis of epidermal papilla
- b. Dermis

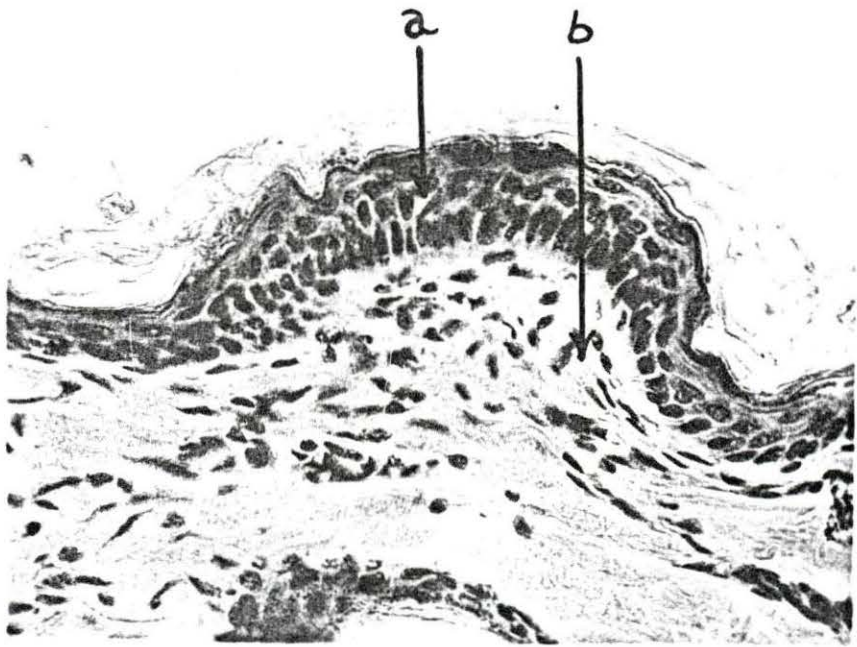


Fig. 12. Epidermal papilla - Section of skin from the interscapular area of a dog 28 weeks of age, fixed in 80 per cent alcohol and stained with Harris' hematoxylin and eosin Y, 90X magnification; a typical group of three compound follicles containing seven to ten hairs each may be observed; an epidermal papilla is observable in the upper center region of the picture

- a. Epidermal papilla
- b. Group of three compound follicles

Fig. 13. Epidermal papilla - Section of skin from the interscapular region of a dog 28 weeks of age, fixed in 80 per cent alcohol and stained with Heidenhain's hematoxylin and Weigert and Van Gieson's connective tissue stain, 180X magnification; in the center of the picture a very well developed epidermal papilla may be observed; note the fine connective tissue substance that fills the papilla

- a. Epidermis of epidermal papilla
- b. Connective tissue of papilla

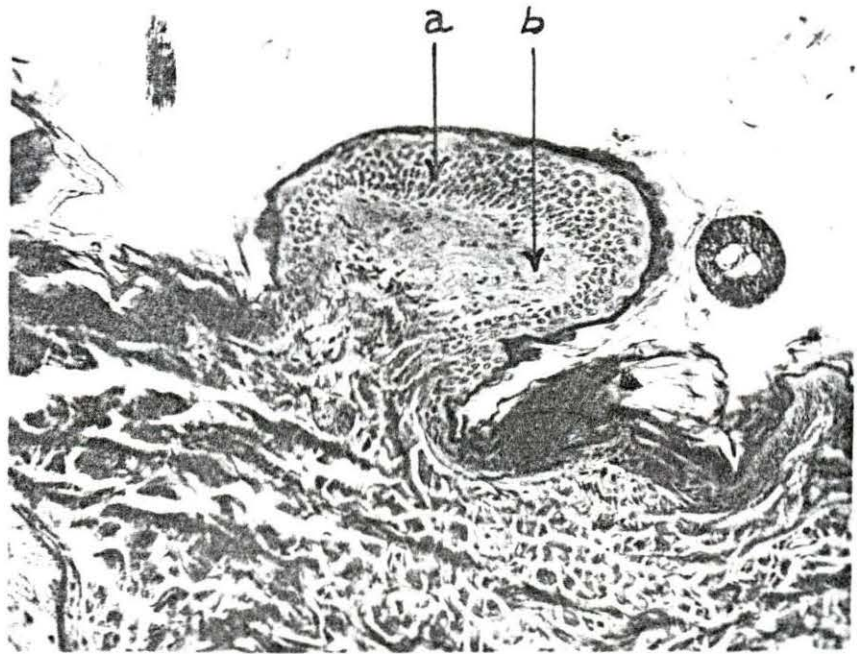
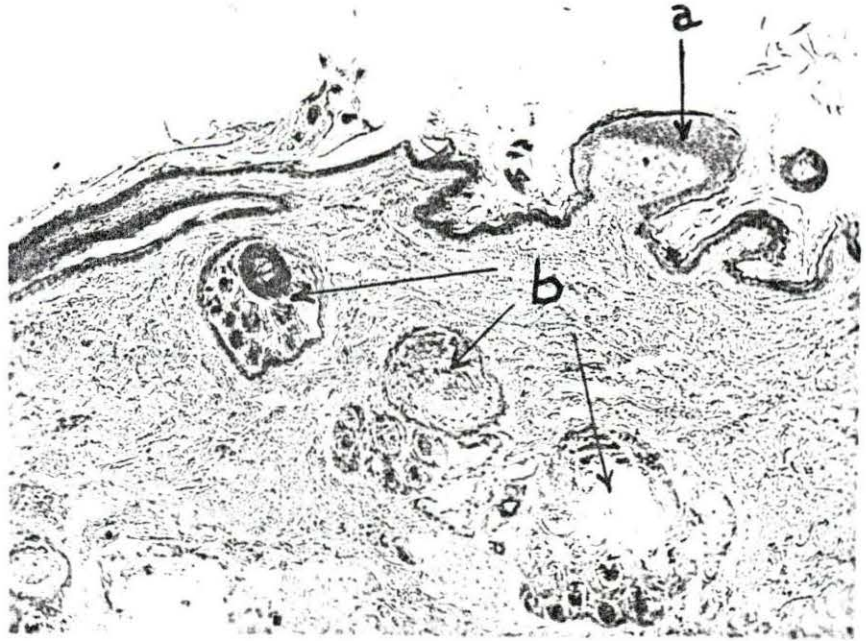


Fig. 14. Clear cells in foot pad epidermis - Section of skin from the front foot pad of a dog three weeks of age, fixed in 80 per cent alcohol and stained with Harris' hematoxylin and eosin Y, 470X magnification; note the clear cells which are present in the basal layers of the epidermis; some dermal papillae are cut on a cross section and appear as islands of dermal tissue surrounded by epidermis; in the upper right corner there is a cross section of a sweat gland excretory duct

- a. Sweat gland excretory duct
- b. Cross section of dermal papilla
- c. Clear cells

Fig. 15. Clear cell in hairy skin - Section of skin from the sacral region of a dog one week of age, fixed in 80 per cent alcohol and stained with Harris' hematoxylin and alcoholic solution of precipitated eosin Y, 470X magnification; in the center of the picture there is a clear cell which is probably a mitotic cell in prophase or metaphase

- a. Epidermis
- b. Dermis
- c. Clear cell

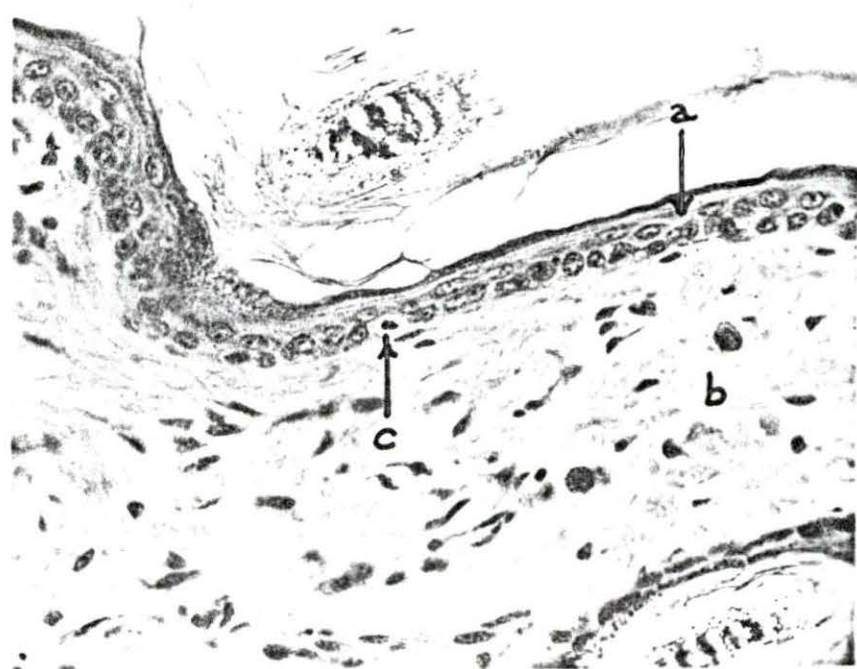
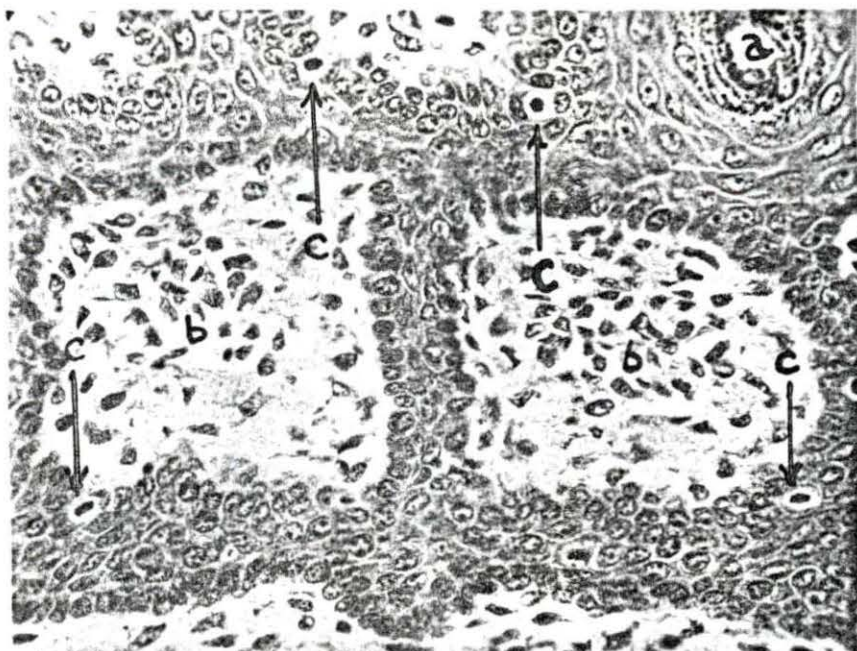


Fig. 16. Mitotic clear cells - Section of skin from the paraumbilical region of a dog one week of age, fixed in 80 per cent alcohol and stained with Harris' hematoxylin and precipitated eosin Y solution, 470X magnification; several clear cells may be observed in various stages of mitosis; the stratum corneum has been separated from the stratum granulosum in sectioning

- a. Stratum corneum
- b. Stratum granulosum
- c. Clear cells in telophase

Fig. 17. Clear cell in telophase - Section of skin from the sacral region of a dog one week of age, fixed in 80 per cent alcohol and stained with a combination of Heidenhain's iron hematoxylin, Van Gieson's acid fuchsin and picric acid stain, and Weigert's stain for elastic fibers, 470X magnification

- a. Clear cell in mitosis (telophase)

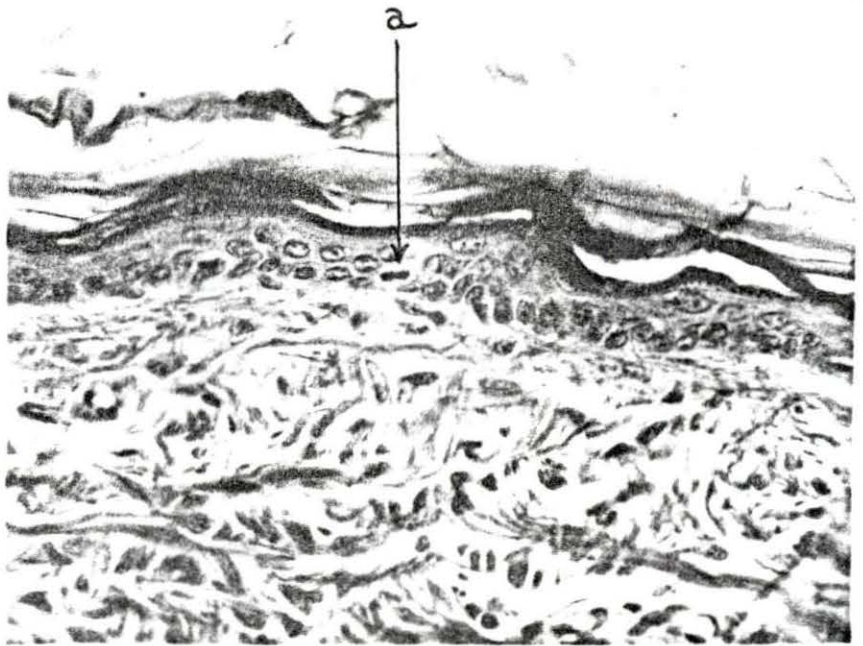
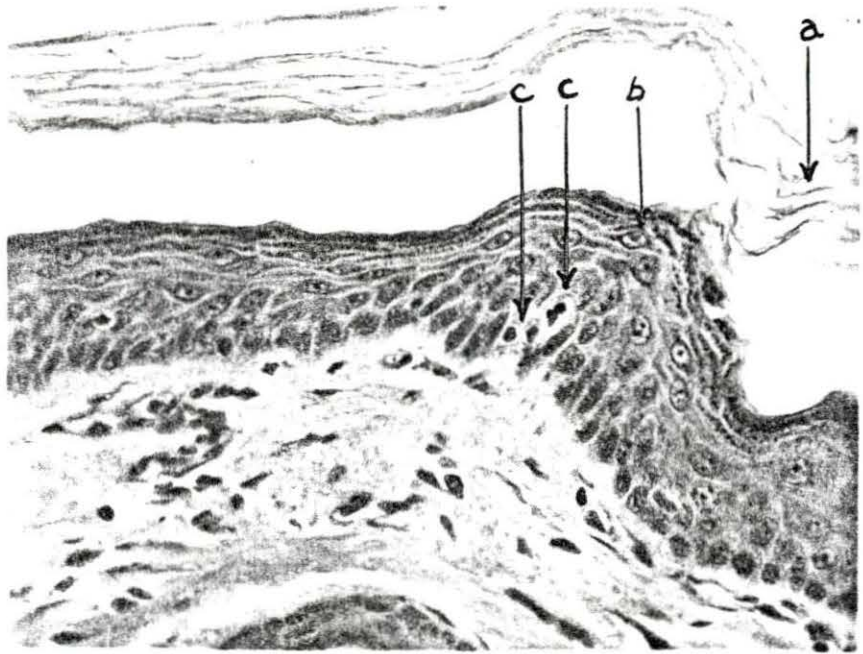


Fig. 18. Glycogen in fused eyelids - Glycogen granules in the epidermis of the fused eyelids of a one day old puppy, fixed in 80 per cent alcohol and stained with Feulgen-Bauer technique; no granules appeared in control sections which were stained simultaneously from which the glycogen had been digested in diastase, 90X magnification; glycogen granules are also present in the hair follicles

- a. Fusion of eyelids
- b. Conjunctiva
- c. Hair follicle
- d. Hairy skin
- e. Glycogen granules

Fig. 19. Glycogen in mucous membrane - Glycogen granules in the epithelium of the mucous membrane of the vulva, fixed in 80 per cent alcohol and stained with Feulgen-Bauer technique, 470X magnification; control sections were stained simultaneously from which the glycogen had been digested in diastase; the granules were not present in the control; the tissue was collected from a dog at birth

- a. Epithelium of mucous membrane
- b. Glycogen granule

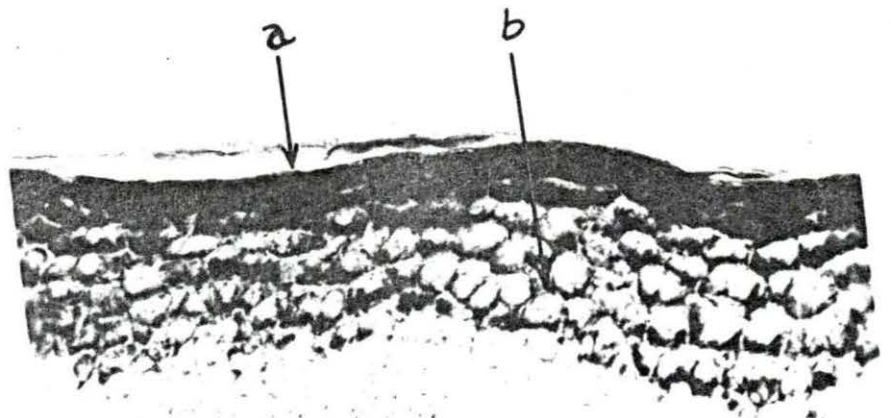
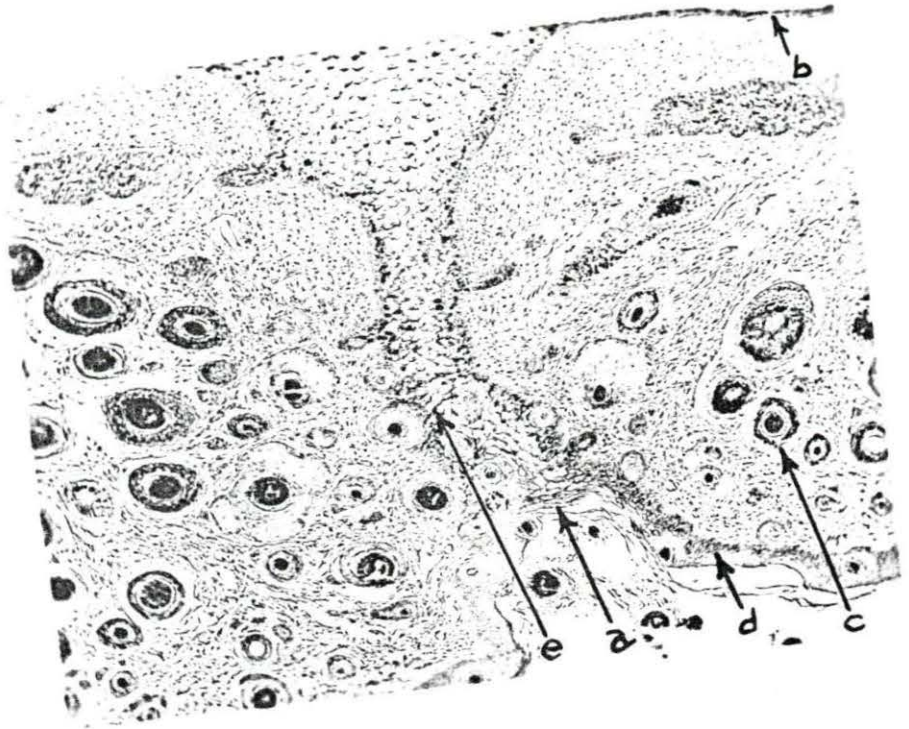


Fig. 20. Alkaline phosphatase in mucous membrane - Section of the mucous membrane of the lip of a three weeks old dog, fixed in 80 per cent alcohol and prepared with the alkaline phosphatase technique of Gomori (three hours incubation), 180X magnification; evidence of the presence of the enzyme, alkaline phosphatase, may be observed in the superficial epithelial cells and the basal cells; the shading of the superficial cells was not present in the control, so it is assumed it indicates the presence of the enzyme; the capillary endothelial cells also show a positive response

- a. Superficial epithelial cells
- b. Basal cells of stratum cylindrum
- c. Capillary endothelium

Fig. 21. Alkaline phosphatase in nasal epidermis - Section of nasal epidermis from a dog at birth, fixed in 80 per cent alcohol and prepared with the alkaline phosphatase technique of Gomori (24 hours incubation), 180X magnification; evidence of the presence of the enzyme, alkaline phosphatase, may be observed in the cells of the basal layer of the epidermis at the depths of the epidermal pegs extending down into the dermis; the darkness in the superficial layers of the epidermis is probably caused by the presence of native phosphate because it was also present in the control section; the nuclei of the fibroblasts of the dermis and the endothelial cells of the capillaries also show a positive response for alkaline phosphatase

- a. Basal cells at the depths of epidermal pegs
- b. Capillary endothelium
- c. Fibroblasts of dermis
- d. Superficial cells

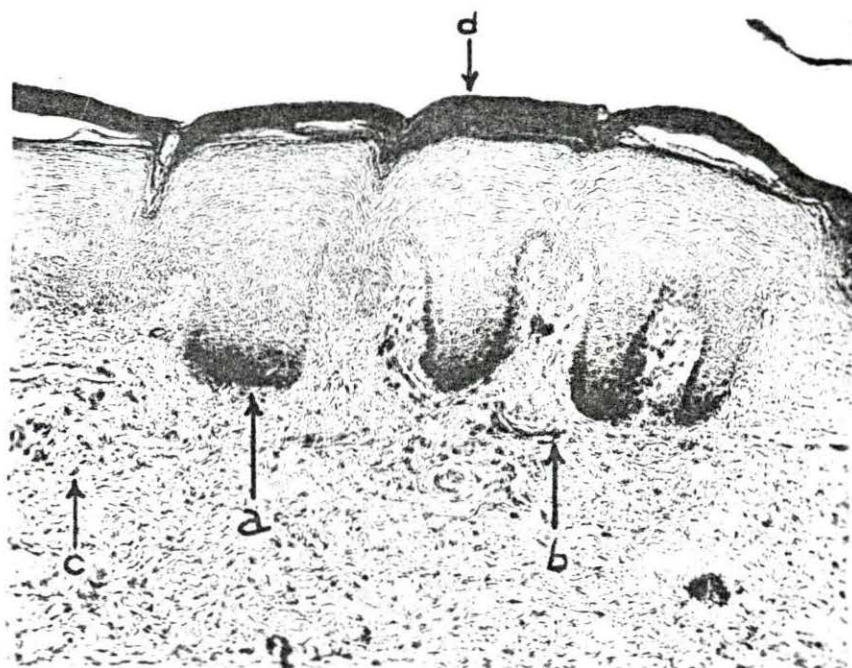
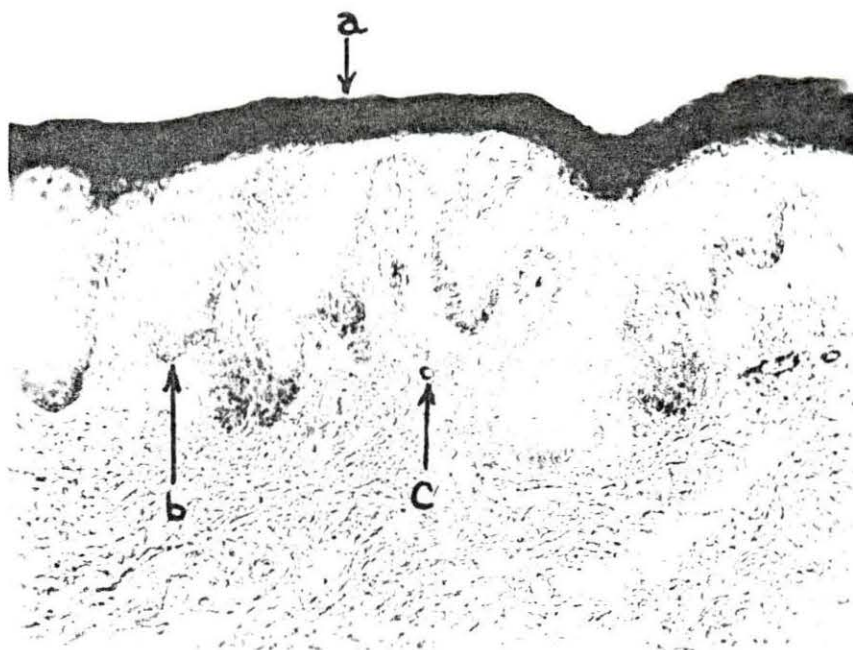


Fig. 22. Pigment cell with dendritic processes - Section of ear flap of dog taken the day of birth, fixed in 80 per cent alcohol and stained with Harris' hematoxylin and eosin Y, 470X magnification; note the melanoblasts in the basal layer of the epidermis; there is one near the center which shows dendritic processes

- a. Stratum corneum
- b. Stratum granulosum
- c. Stratum spinosum
- d. Stratum cylindricum
- e. Melanoblast
- f. Dermis

Fig. 23. Fibroblasts in epidermis - Section of skin from the interscapular region of a dog one week of age, fixed in 10 per cent formalin and stained with Harris' hematoxylin and precipitated eosin Y, 470X magnification; fibroblasts are observable between the cells of the stratum cylindricum or basal cells of the epidermis

- a. Stratum corneum
- b. Stratum granulosum (keratohyalin granules)
- c. Stratum spinosum
- d. Stratum cylindricum
- e. Fibroblasts
- f. Dermis

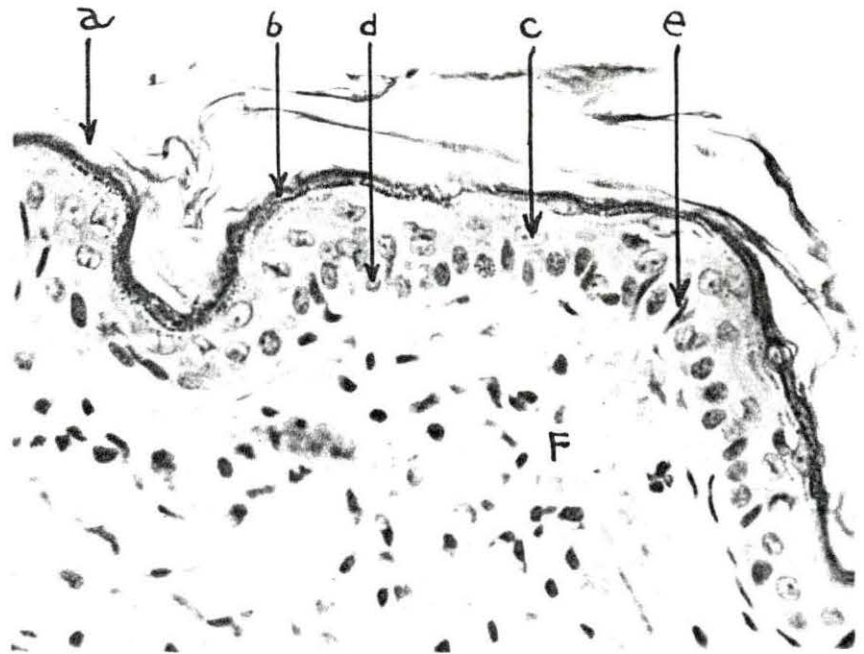
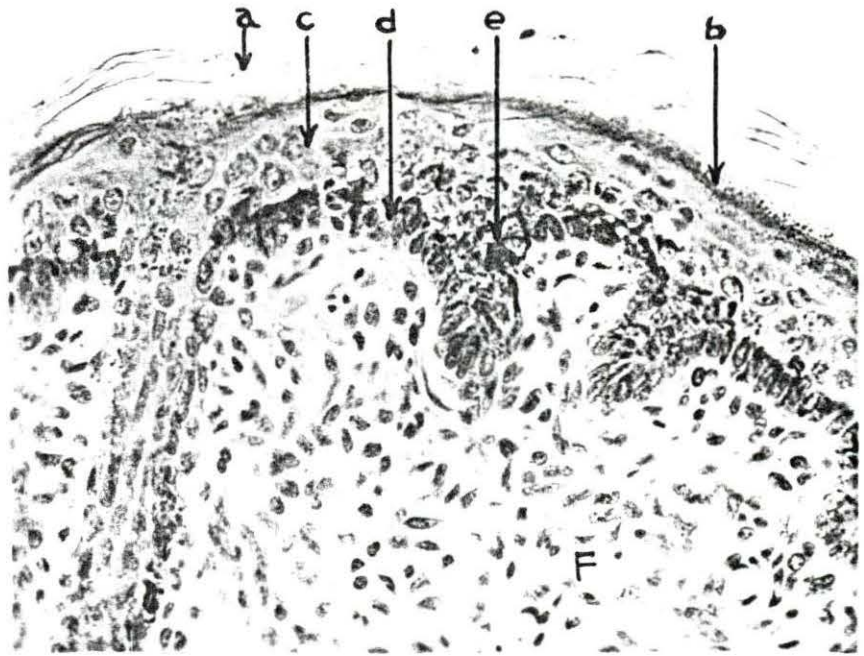


Fig. 24. Section of lip - Section of lip of one week old dog, fixed in 80 per cent alcohol and stained with Harris' hematoxylin and eosin Y, 15X magnification; note the undulation of the epidermal-dermal junction on the mucous membrane and non-hairy portion and the absence of epidermal pegging on the hairy part

- a. Mucous membrane
- b. Hairy skin epidermis
- c. Epidermal peg
- d. Area of Fig. 25
- e. Muscle

Fig. 25. Mucocutaneous junction of lip - Section of lip of one week old dog, fixed in 80 per cent alcohol and stained with Harris' hematoxylin and eosin Y, 90X magnification; note the epidermal pegging of the non-hairy part of the lip; note also the size of the sebaceous and apocrine glands that are associated with the hair follicles near the mucocutaneous junction

- a. Epidermal peg
- b. Mucocutaneous junction
- c. Sebaceous gland
- d. Apocrine gland
- e. Hair follicle

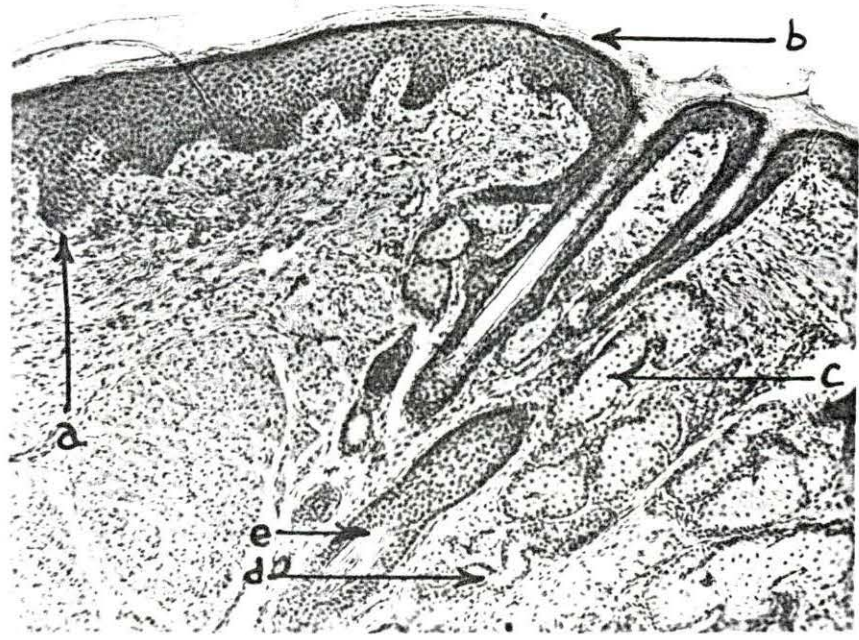
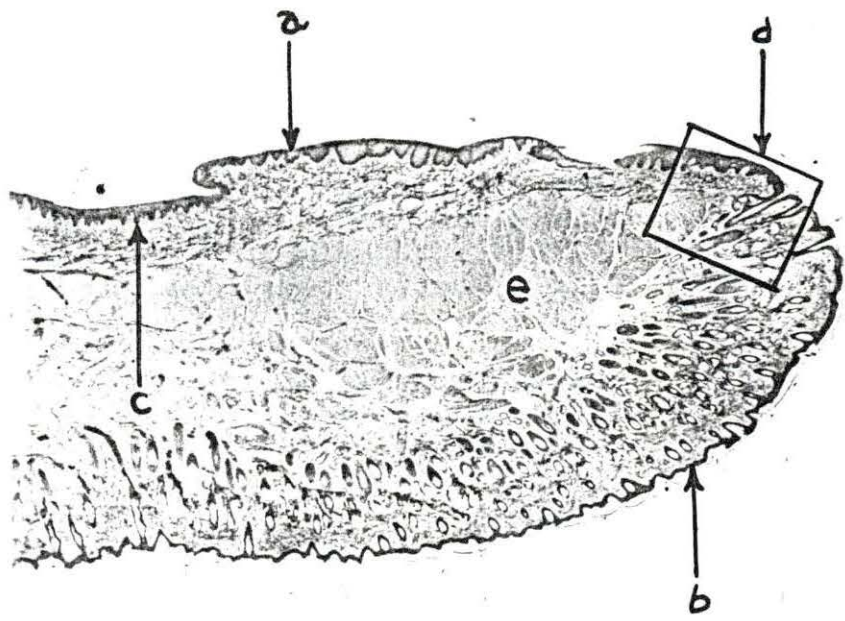


Fig. 26. Elastic fibers connected to arrector pili muscle - Section of skin from interscapular region of a dog 24 weeks of age, fixed in 80 per cent alcohol and stained with Weigert and Van Gieson's connective tissue stain, 180X magnification; note the elastic fibers extending from the end of the arrector pili muscle toward the surface epithelium

- a. Arrector pili muscle
- b. Hair follicle
- c. Epidermis
- d. Elastic fiber
- e. Dermis

Fig. 27. Elastic fibers - Section of skin from the sacral region of a dog 28 weeks of age, fixed in 80 per cent alcohol and stained with Weigert and Van Gieson's connective tissue stain, 470X magnification; note the branching elastic fibers mixed in with the collagenous fibers in the dermis near a hair follicle

- a. Elastic fiber
- b. Collagenous fiber
- c. Hair follicle

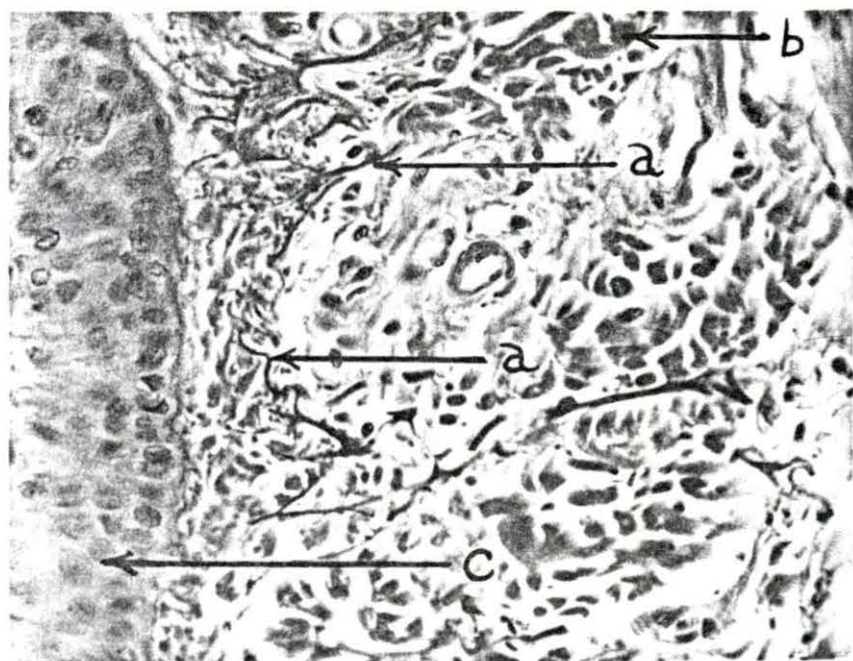
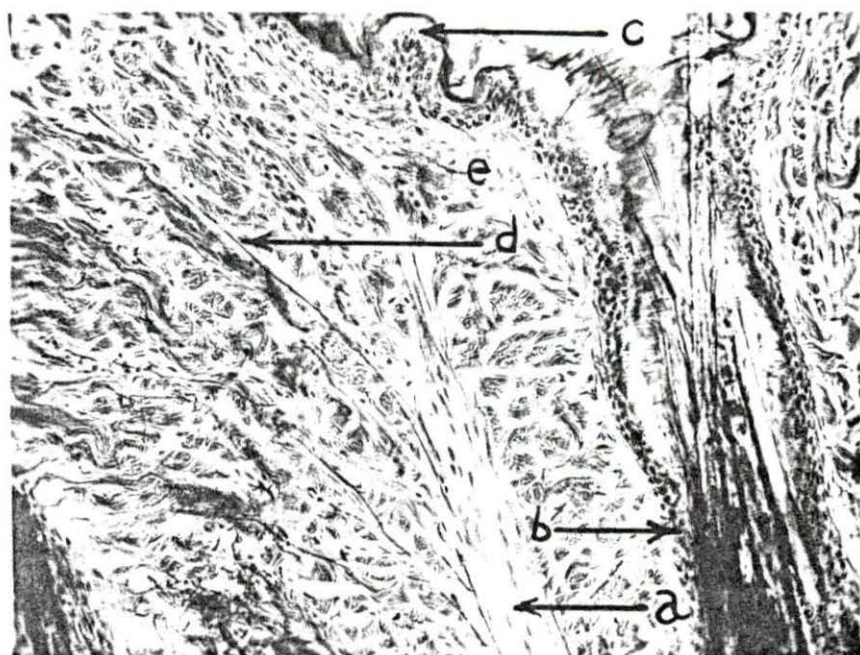


Fig. 28. Reticular network - Section of skin from the interscapular region of a mature dog, fixed in 10 per cent formalin and stained with Foot and Menard rapid silver impregnation method, 90X magnification; reticular fibers may be observed forming a network around hair follicles, sebaceous glands, arrector pili muscles, and apocrine glands; collagenous fibers appear thicker and lighter

- a. Reticular fibers
- b. Collagenous fibers
- c. Sebaceous gland
- d. Hair follicle

Fig. 29. Reticular network - High power picture of the same section as Fig. 28, 470X magnification; reticular fibers may be seen around the hair follicles, sebaceous glands, and arrector pili muscle

- a. Reticular fibers
- b. Sebaceous gland

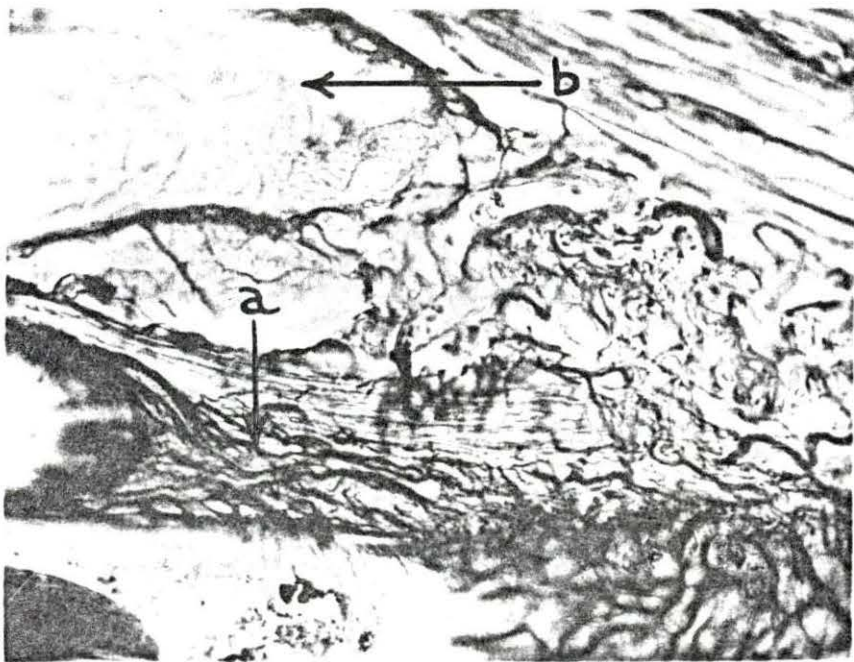
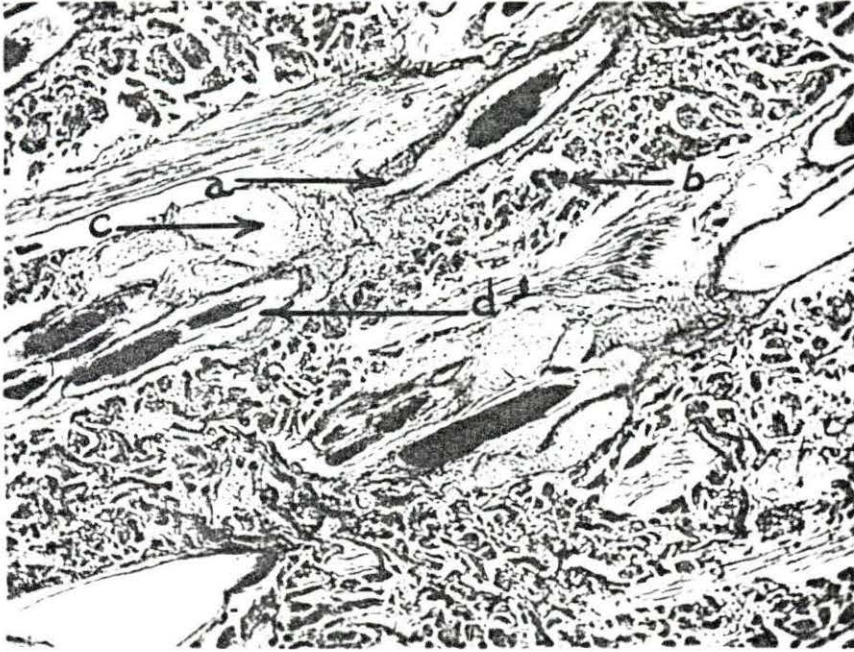

Fig. 30. Reticular network - Section of paraumbilical skin from a dog three weeks of age, fixed in 80 per cent alcohol and prepared with Foot and Menard rapid method of silver impregnation, 835X magnification; evidence may be observed that the so-called basement membrane is made up of a network of fine reticular fibers which interdigitate between the basal cells of the epidermis

- a. Epidermis
- b. Stratum cylindricum
- c. Reticular fibers

Fig. 31. Reticular network - Section of the conjunctival mucous membrane from the eyelid of a dog eight weeks of age, fixed in 80 per cent alcohol and prepared with Foot and Menard rapid method of silver impregnation, 470X magnification; a network of reticular fibers may be observed under the epithelium which appear to be continuous deeply with the thicker collagenous bundles

- a. Epithelium
- b. Reticular network
- c. Collagenous fibers

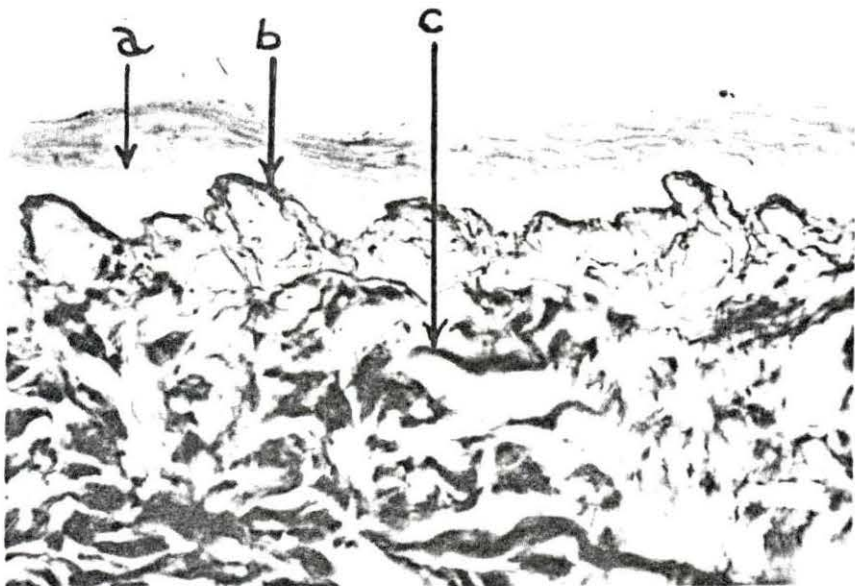
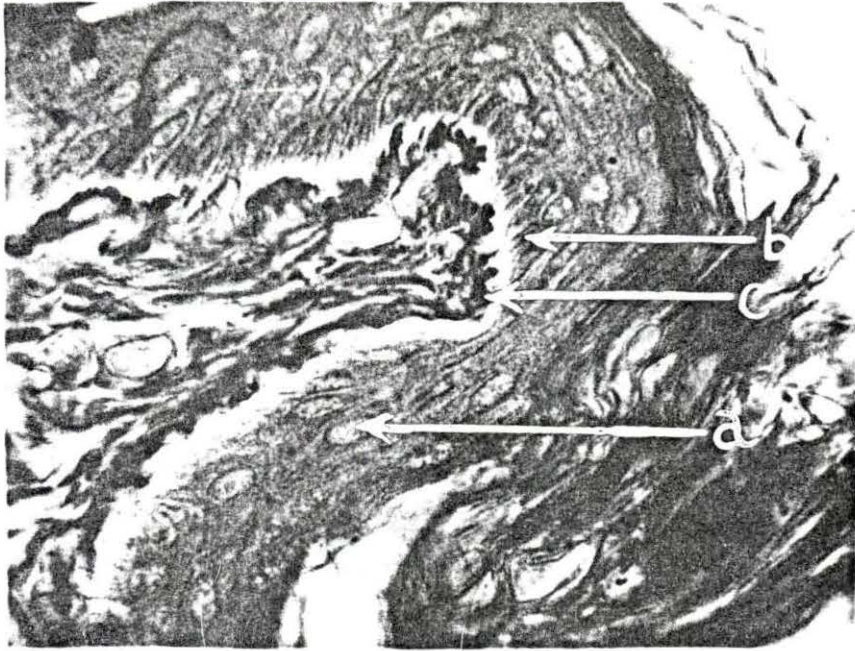


Fig. 32. Reticular fibers interdigitating with basal cells - Section from the front foot pad of a dog eight weeks of age, fixed in 10 per cent formalin and prepared with the Foot and Menard rapid method of silver impregnation, 835X magnification; fibroblasts may be observed between the basal cells of the epidermis and the reticular fibers of the dermis may be observed extending up between the basal cells of the epidermis in the vicinity of the fibroblasts

- a. Basal cell of stratum cylindricum
- b. Fibroblast
- c. Reticular fiber
- d. Spinous cell of stratum spinosum

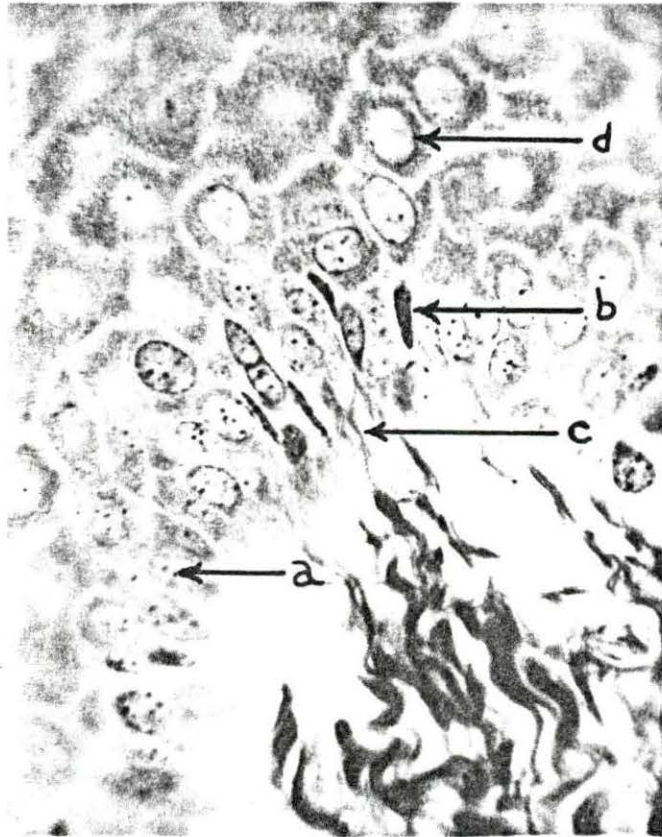


Fig. 33. Reticular and collagenous fibers - Section of front foot pad from a two weeks old dog which has been fixed in 80 per cent alcohol and treated with the Foot and Menard rapid method of silver impregnation, 470X magnification; the epithelial cells are heavily pigmented; reticular fibers may be observed directly under the epidermis which form a network; these reticular fibers appear to be continuous with the lighter staining collagenous fibers which are located deeper in the dermis

- a. Epidermal cells
- b. Pigment granules
- c. Reticular fibers
- d. Collagenous fibers

Fig. 34. Reticular fibers interdigitating between basal cells - Section of nasal epidermis from a dog four weeks of age, fixed in 10 per cent formalin and treated with the Foot and Menard rapid method of silver impregnation (modified), 835X magnification; reticular fibers may be observed interdigitating between the basal cells of the epidermis; intercellular bridges may be observed in the upper right hand corner

- a. Basal cell of stratum cylindricum
- b. Reticular fiber
- c. Spinous cell with intercellular bridges

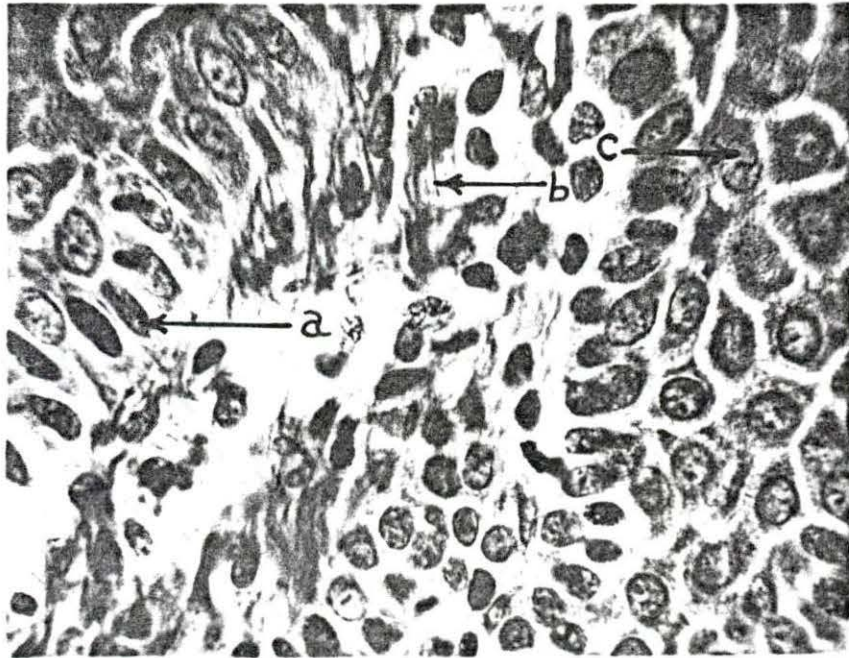



Fig. 35. Sensory lamellar corpuscle - Section of subcutaneous tissue of the front foot pad of a four week old dog, fixed in 80 per cent alcohol and prepared with the Feulgen-Bauer technique (this slide was a control), 180X magnification; note the lamellar corpuscle in the center of the picture

a. Lamellar corpuscle

Fig. 36. Sensory lamellar corpuscle - Section of the subcutaneous tissue of the front foot pad of a 12 week old dog, fixed in 80 per cent alcohol and prepared with the Gomori technique for alkaline phosphatase, incubation time 24 hours, 470X magnification; note the lamellar corpuscle with alkaline phosphatase activity in the center

a. Lamellar corpuscle

b. Center of alkaline phosphatase activity

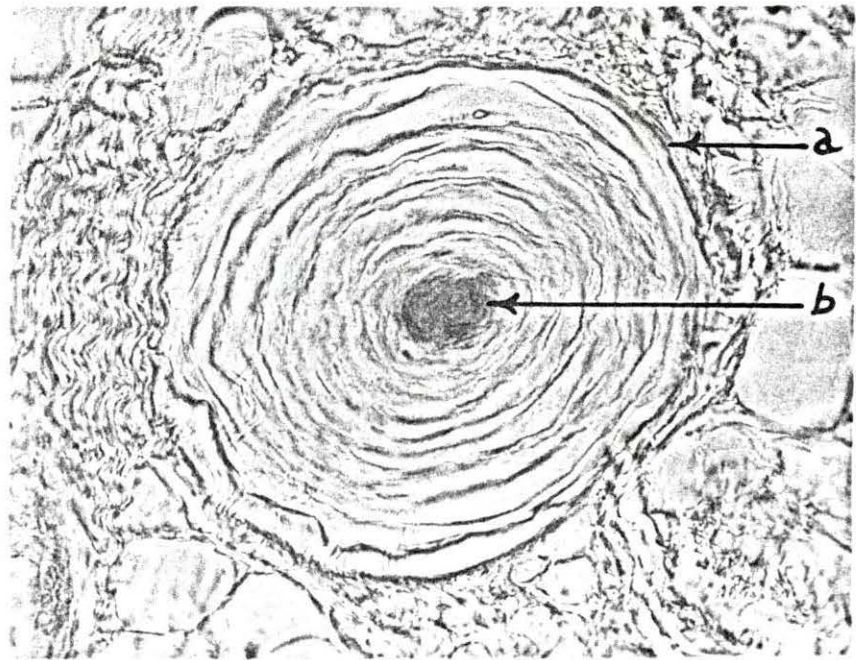
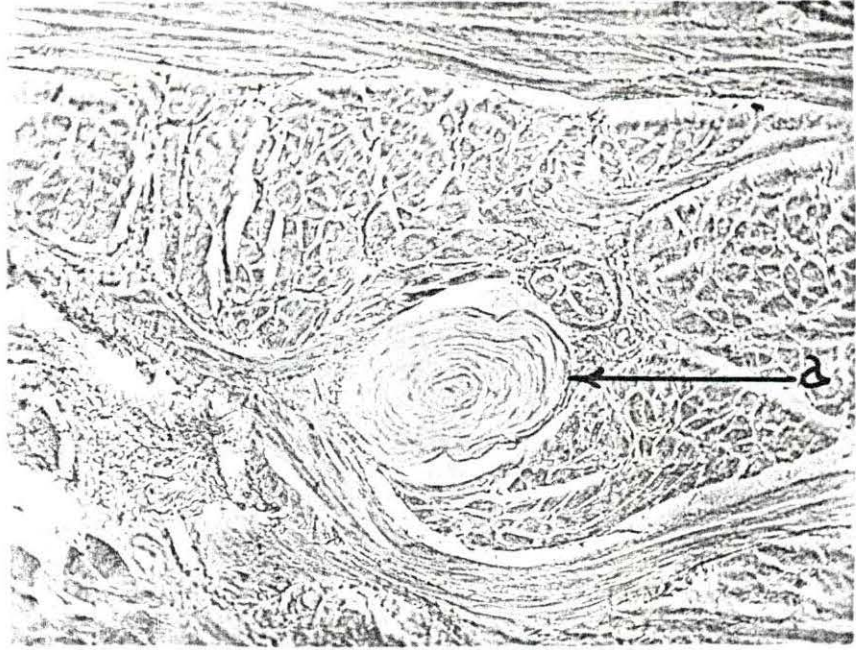

Fig. 37. Simple hair follicle at birth - Cross section of a hair and hair follicle from a dog shortly after birth, fixed in 80 per cent alcohol and stained with Harris' hematoxylin and eosin Y, 470X magnification; notice that this is a single hair follicle with a single hair, this is typical of the follicles of dog skin from dogs less than a week old; apocrine glands may also be observed on each side of the follicle

- a. Hair follicle
- b. Hair
- c. Apocrine gland

Fig. 38. Two or three hairs in a follicle at four weeks - Section of skin from the interscapular region of a dog four weeks of age, fixed in 80 per cent alcohol and stained with Harris' hematoxylin and precipitated eosin Y solution, 90X magnification; in the cross sections of the hair follicles, it may be observed that there are two hairs in each follicle superficially and more deeply they branch or separate into two individual hair bulbs

- a. Hair shaft
- b. Hair follicle containing two hairs
- c. Epidermis
- d. Dermis
- e. Subcutis

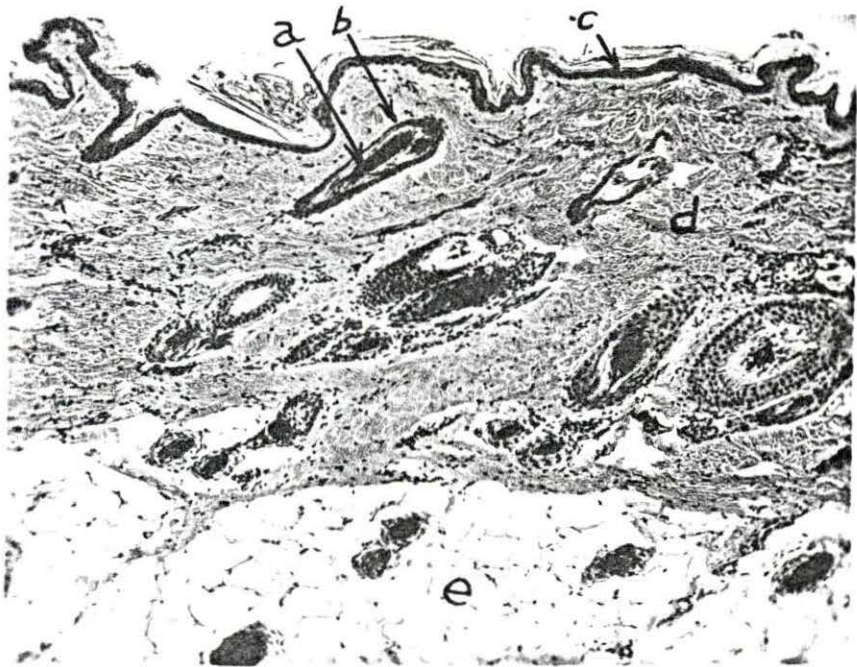
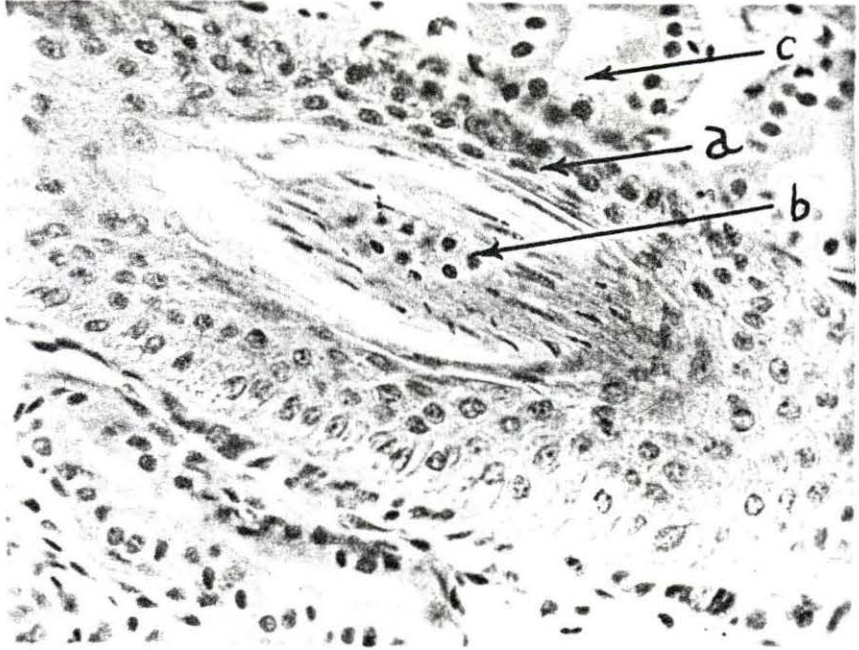


Fig. 39. Four to six hairs in a follicle at ten weeks - Section of skin above the eye from a dog ten weeks of age, fixed in 80 per cent alcohol and stained with Harris' hematoxylin and alcoholic solution of precipitated eosin Y, 79X magnification; this section shows that the compound hair follicles of the dog's skin are for the most part arranged in groups of three; also it may be observed that there are from four to six hairs in each follicle

- a. A group of three follicles
- b. Five hairs in one follicle
- c. Sebaceous gland

Fig. 40. Ten hairs in a follicle at 28 weeks - Section of skin from the flank region of a dog 28 weeks of age, fixed in 80 per cent alcohol and stained with Harris' hematoxylin and eosin Y, 180X magnification; the picture shows a cross section of a compound hair follicle which contains ten hairs; note the excretory duct of an apocrine gland on the lower side of the follicle

- a. Compound hair follicle
- b. Main hair
- c. Auxiliary hairs
- d. Apocrine gland duct

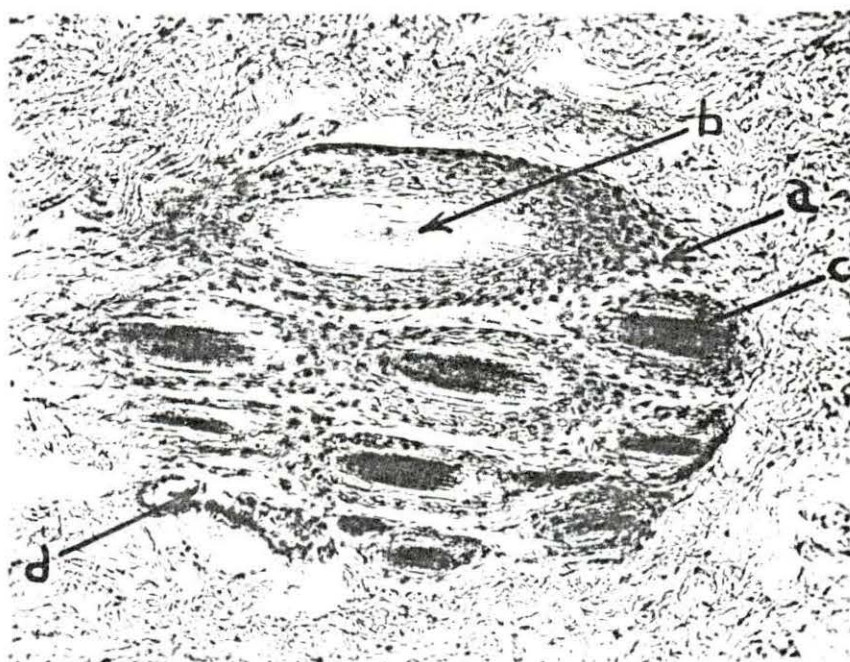
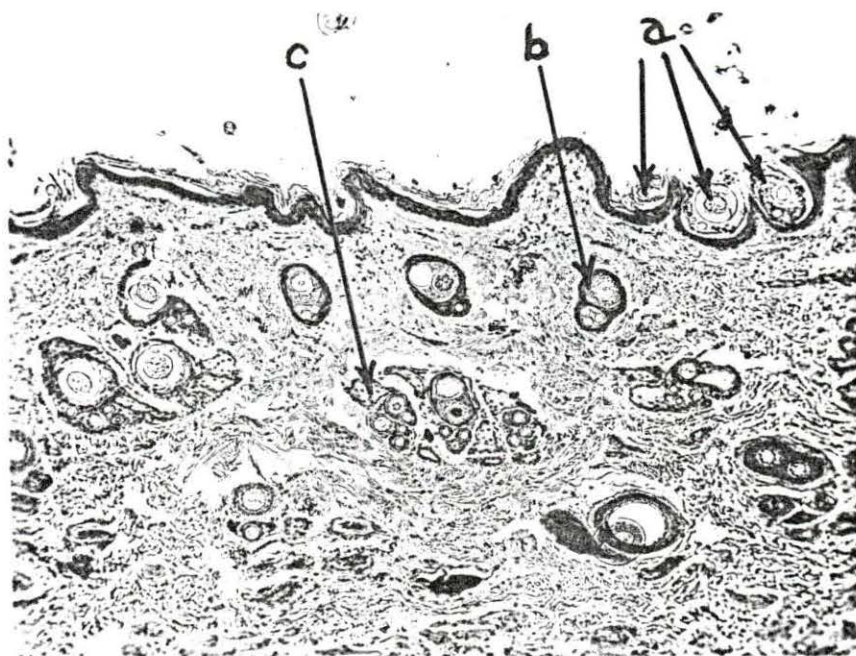


Fig. 41. Developing follicles - Section of earflap of dog collected shortly after birth, fixed in 80 per cent alcohol and stained with Harris' hematoxylin and eosin Y, 180X magnification; note the developing hair follicles extending into the dermis

- a. Epidermis
- b. Developing follicle
- c. Mature follicle

Fig. 42. Sinus hair follicle - Section of lip of dog three weeks of age, fixed in 80 per cent alcohol and prepared with the Gomori technique for the demonstration of alkaline phosphatase, six hours incubation, 90X magnification; the picture shows a tangential section of a sinus hair follicle and a sebaceous gland duct opening into the hair follicle

- a. Hair follicle
- b. Sebaceous gland
- c. Blood sinus
- d. Connective tissue sheath of sinus
- e. Apocrine gland of adjacent follicle

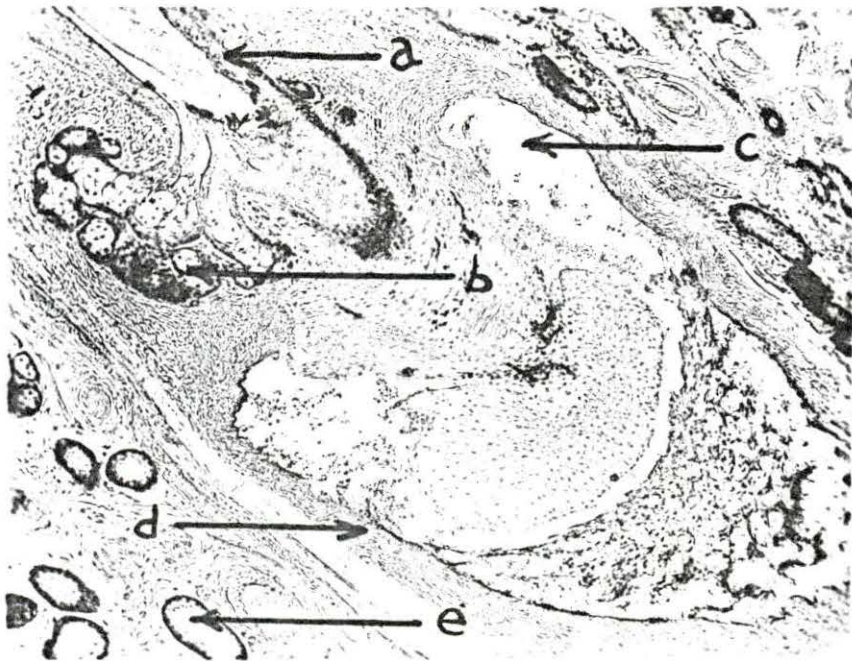
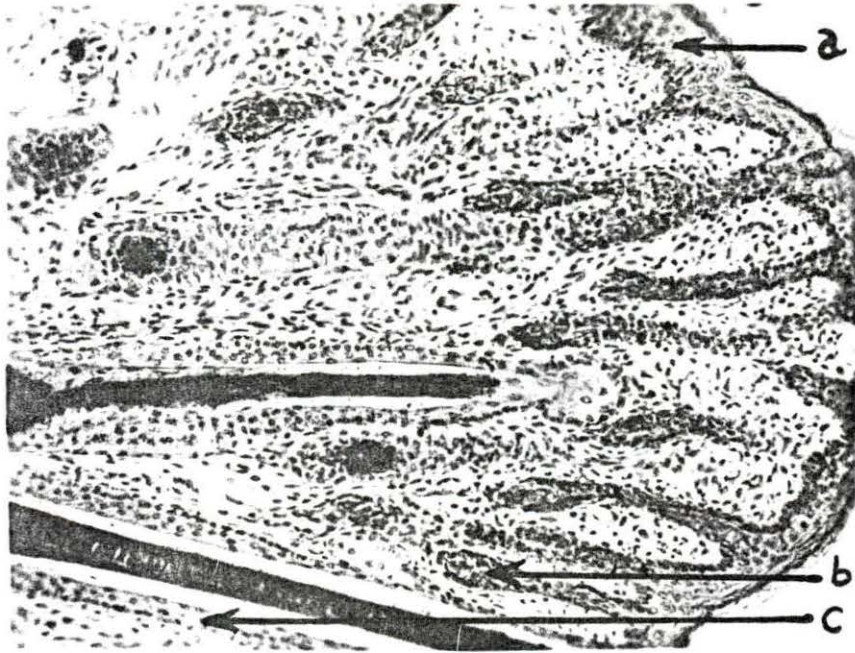


Fig. 43. Glycogen in hair follicles - Section of skin from interscapular region of a dog one week of age, fixed in 80 per cent alcohol and prepared with the Fuelgen-Bauer technique for the demonstration of glycogen, 90X magnification; note the glycogen in the outer root sheaths of the hair follicles and in the arrector pili muscles

- a. Outer root sheat containing glycogen granules
- b. Arrector pili muscles containing glycogen
- c. Epidermis

Fig. 44. Alkaline phosphatase in hair papilla and matrix - Section of skin from the interscapular area of a dog one week of age, fixed in 80 per cent alcohol and prepared with the Gomori technique for the demonstration of alkaline phosphatase, incubation six hours, 470X magnification; hair matrix and dermal papilla may be observed; note the intense reaction for alkaline phosphatase in the dermal papilla and the moderate reaction of the nuclei of the matrix cells

- a. Hair matrix
- b. Dermal papilla

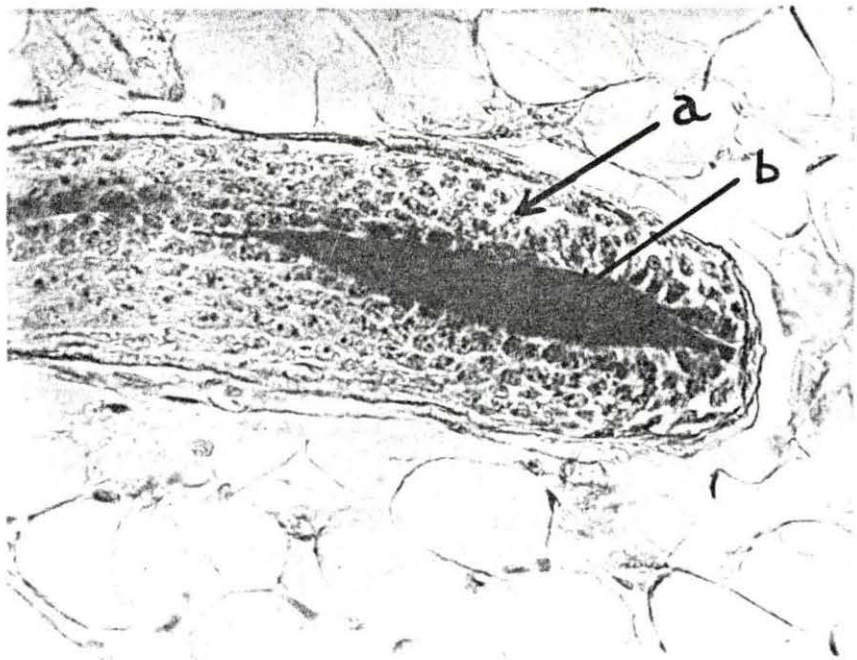
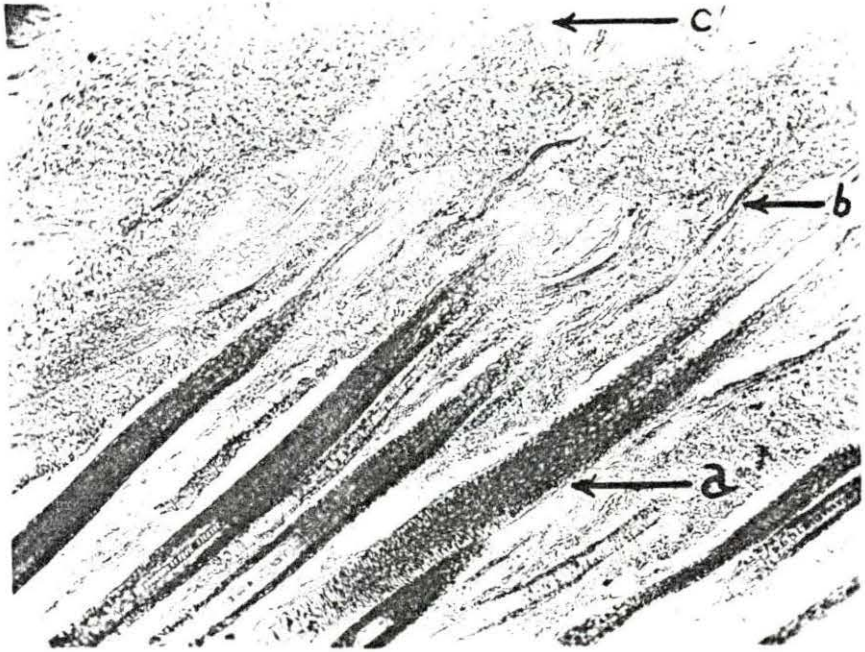


Fig. 45. Sweat gland opening into hair follicle - Section of skin from the interscapular area of a dog one week old, fixed in 80 per cent alcohol and stained with Weigert and Van Gieson's connective tissue stain, 90X magnification; the picture shows the duct of an apocrine gland emptying into a hair follicle

- a. Hair follicle
- b. Secretory portion of apocrine gland
- c. Excretory duct of apocrine gland
- d. Sebaceous gland
- e. Point where gland opens into follicle

Fig. 46. Sweat gland opening into hair follicle - Section of skin from the interscapular region of a dog one week of age, fixed in 80 per cent alcohol and prepared with the Gomori technique for the demonstration of alkaline phosphatase, 24 hours incubation, 90X magnification; note the apocrine gland tubule emptying into the hair follicle above the level of the sebaceous gland

- a. Hair follicle
- b. Secretory portion of apocrine gland
- c. Excretory duct of apocrine gland
- d. Sebaceous gland
- e. Arrector pili muscle
- f. Point where gland opens into follicle

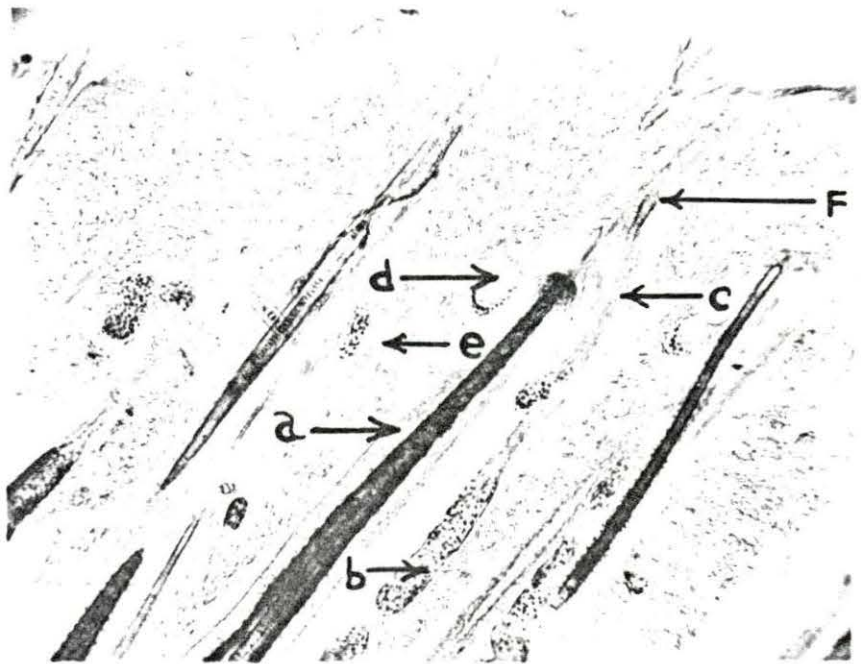
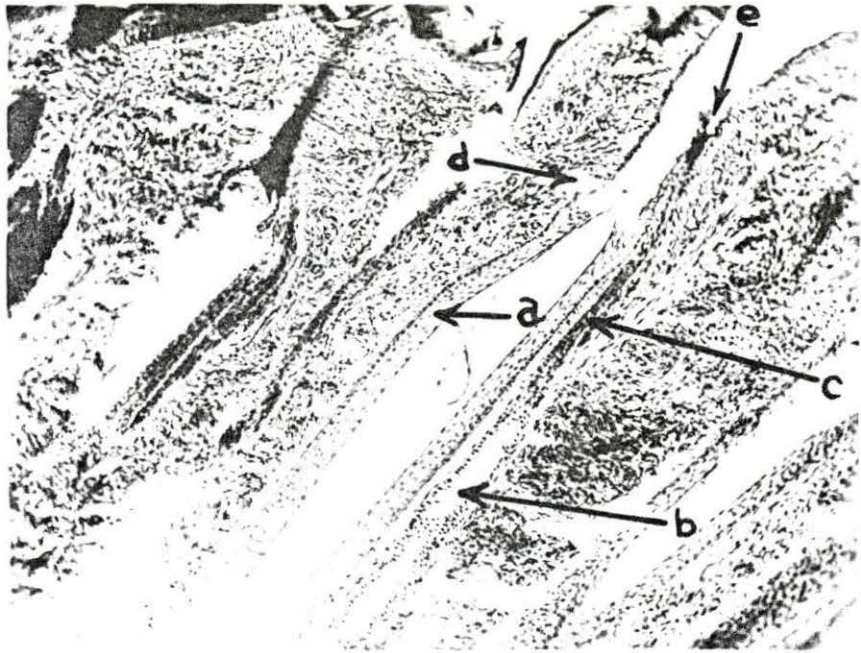


Fig. 47. Dilated apocrine tubules - Section of skin from the fold of the flank of a dog eight weeks of age, fixed in 80 per cent alcohol and stained with Harris' hematoxylin and eosin Y, 90X magnification; a series of cross sections of the secretory portion of an apocrine gland may be observed in the subcutaneous tissue; an excretory duct, smaller in diameter than the secretory tubule may be observed winding up toward the hair follicle and the surface

- a. Secretory portion of apocrine gland
- b. Excretory duct
- c. Hair follicle
- d. Epidermis
- e. Dermis
- f. Subcutis
- f. Sebaceous gland

Fig. 48. Active apocrine gland - Section of skin from the vulva of a dog three weeks of age, fixed in 80 per cent alcohol and stained with Harris' hematoxylin and eosin Y, 470X magnification; note the apical processes of the secretory cells of the apocrine tubule c.; tubule d. represents the post-secretory stage

- a. Apical process of apocrine cell
- b. Apocrine cell
- c. Pre-secretory tubule
- d. Post-secretory tubule

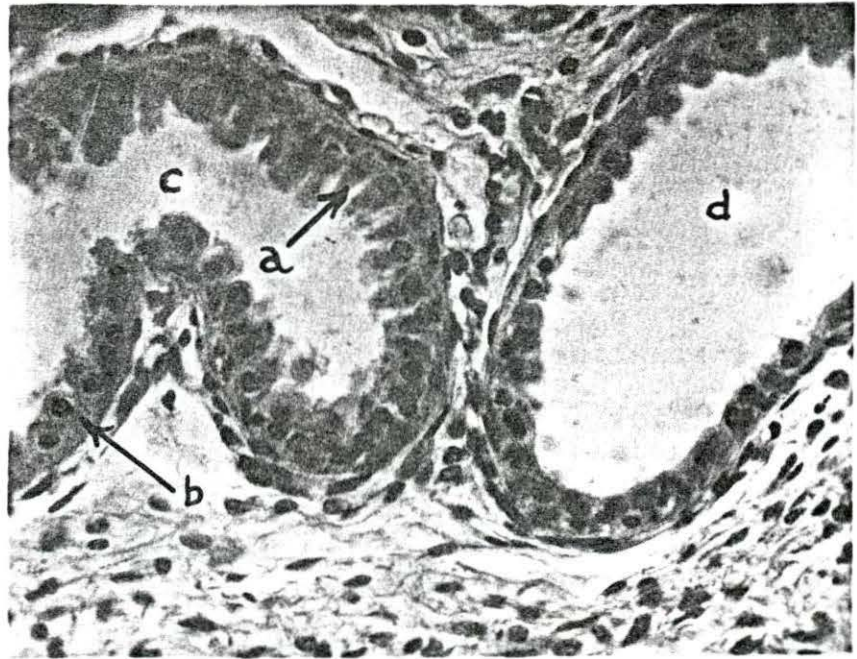
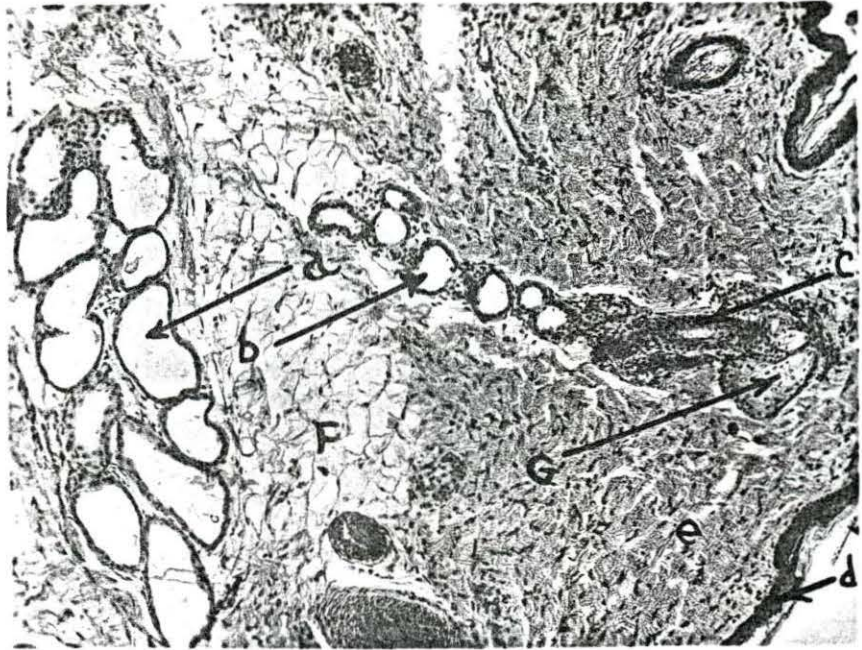

Fig. 49. Glycogen in merocrine gland - Section of front foot pad from dog two weeks of age, fixed in 80 per cent alcohol and prepared with the Feulgen-Bauer technique for the demonstration of glycogen, 470X magnification; note the glycogen granules in the cytoplasm of the merocrine gland cells

- a. Merocrine gland tubule
- b. Glycogen granules

Fig. 50. Apocrine glands showing myoepithelial cells - Section of lip of a dog three weeks of age, fixed in 80 per cent alcohol and prepared with the Gomori technique for the demonstration of alkaline phosphatase, six hours incubation, 470X magnification; note the very intense reaction of the myoepithelial cells and their processes; note also that the nuclei of the secretory cells show evidence of alkaline phosphatase activity; the apical cytoplasmic projections into the lumen are characteristic of apocrine glands

- a. Apocrine secretory cell
- b. Fibroblast
- c. Myoepithelial cell
- d. Capillary endothelium

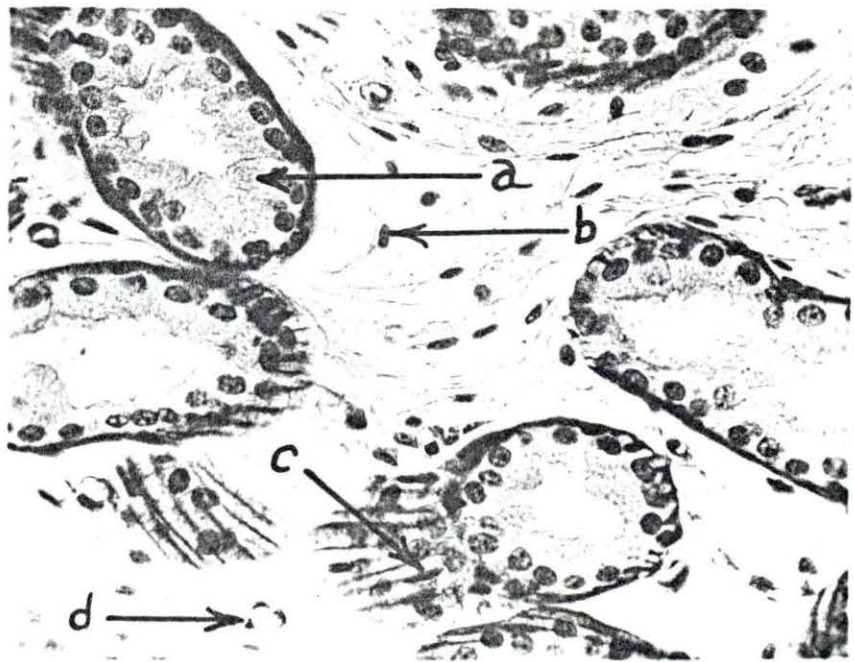
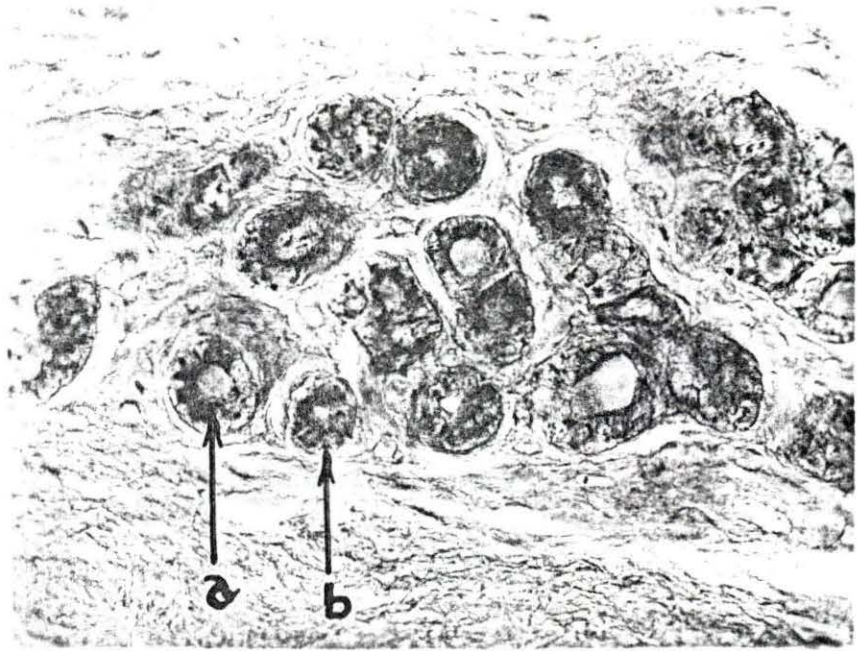


Fig. 51. Phosphatase in merocrine glands - Section of subcutaneous tissue of the hind foot pad of a dog ten weeks of age, fixed in 80 per cent alcohol and prepared with the Gomori technique for the demonstration of alkaline phosphatase, 24 hours incubation, 470X magnification; note the reaction of the nuclei of the secretory cells and the fibroblast nuclei and the myoepithelial cells

- a. Merocrine secretory cell
- b. Myoepithelial cell
- c. Fibroblast
- d. Fat cell

Fig. 52. Merocrine gland - Section of hind foot pad of a dog 12 weeks of age, fixed in 80 per cent alcohol and stained with Harris' hematoxylin and eosin Y, 470X magnification; the picture shows subcutaneous fat cells and cross sections of the merocrine secretory tubules; myoepithelial cells may also be observed

- a. Fat cell
- b. Merocrine secretory cell
- c. Myoepithelial cell

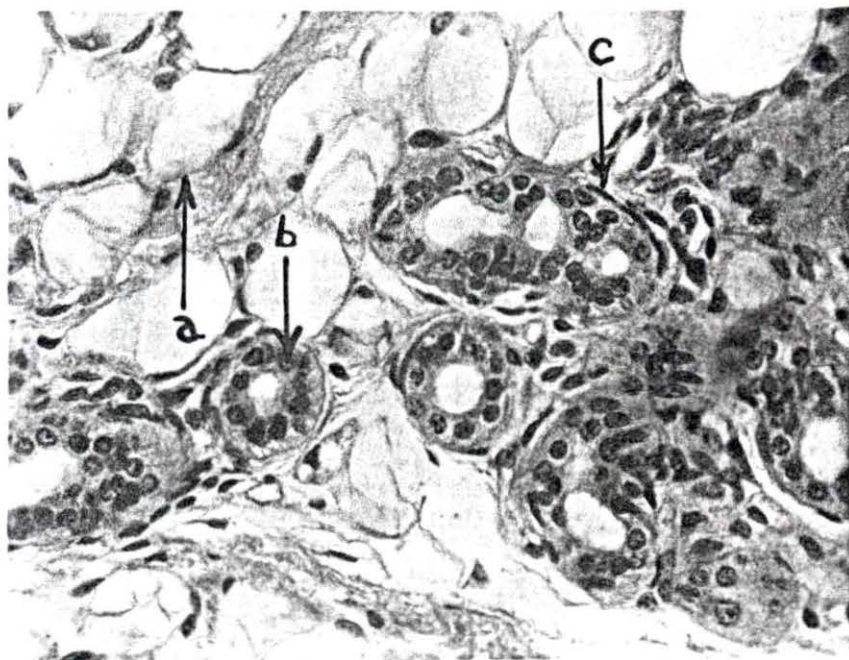
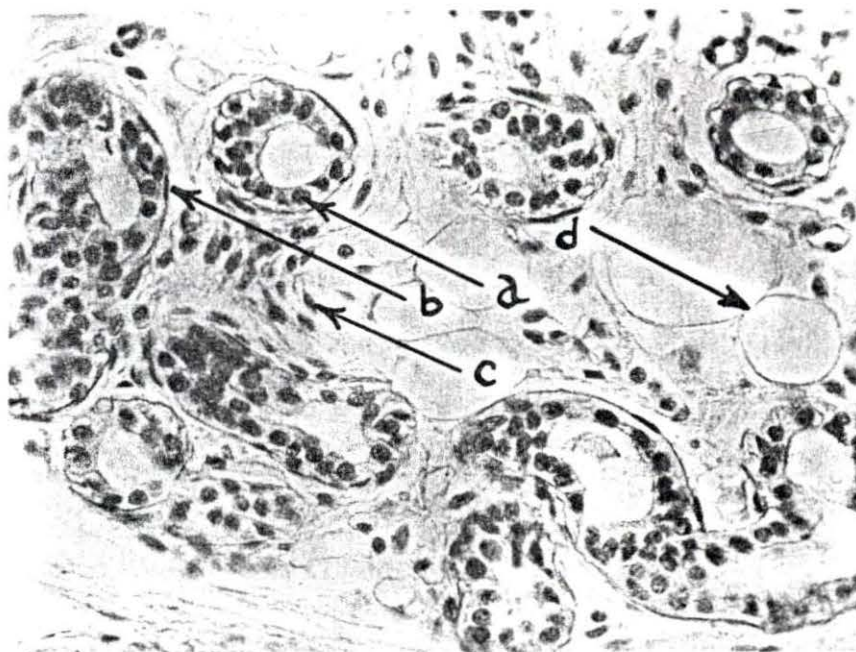

Fig. 53. Alkaline phosphatase activity in a sebaceous gland - Section of lip of dog three weeks of age, fixed in 80 per cent alcohol and prepared with the Gomori technique for the demonstration of alkaline phosphatase activity, six hours incubation, 470X magnification; note the very intense reaction of the peripheral sebaceous cells and the moderate to slight reaction of the nuclei of the central cells

- a. Peripheral sebaceous cells
- b. Central sebaceous cells
- c. Apocrine gland tubule
- d. Hair follicle

Fig. 54. Meibomian gland - Section of eyelid of a dog eight weeks old, fixed in 80 per cent alcohol and stained with hematoxylin and eosin Y, 90X magnification; note the large modified sebaceous gland at the margin of the lid

- a. Meibomian gland
- b. Epidermis
- c. Dermis
- d. Sebaceous gland and hair follicle
- e. Conjunctiva

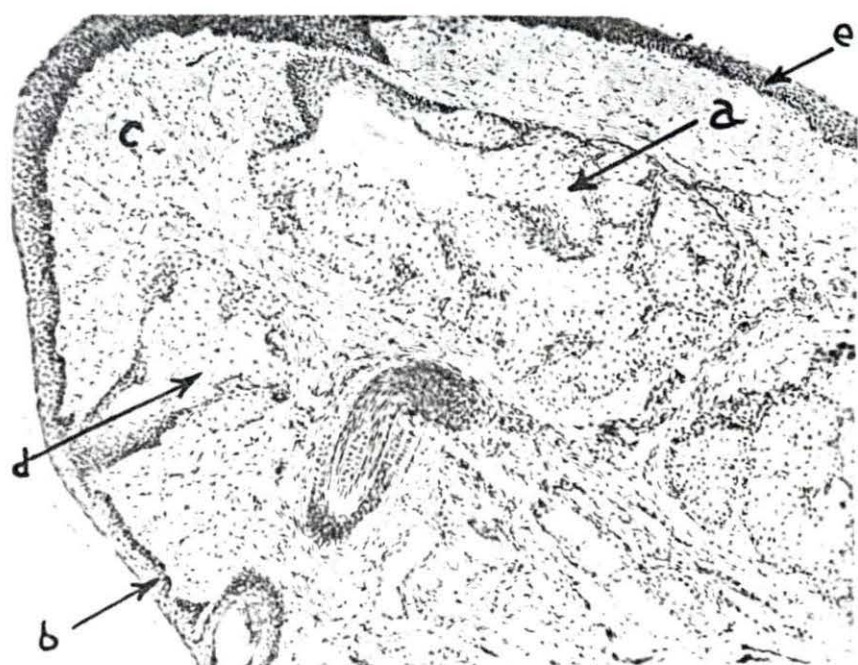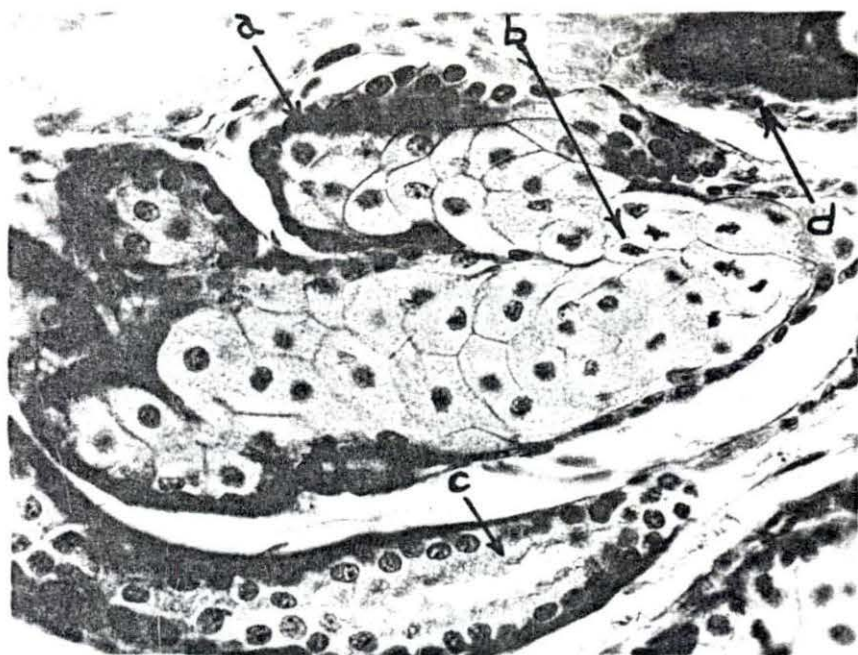


Fig. 55. Glycogen in arrector pili muscle - Section of skin from the sacral region of an eight week old dog, fixed in 80 per cent alcohol and prepared with the Feulgen-Bauer technique for glycogen, 90X magnification; note the glycogen in the arrector pili muscle and outer root sheath of hair follicles

- a. Epidermis
- b. Dermis
- c. Arrector pili muscle
- d. Hair follicle
- e. Glycogen granules
- f. Sebaceous gland

